



6, 2020, 190 nations or regions had reported more than 48.7 million COVID-19 infections, which led to more than 1.23 million fatalities.<sup>[3]</sup>

This article's primary goal is to determine whether the incidence of dry socket following routine oral surgical procedures at NSVK Sri Venkateshwara Dental College and Hospital, Bengaluru, in the Department of Oral and Maxillofacial Surgery increased during the COVID-19 pandemic.

The majority of procedures performed by departments of oral surgery are dental extractions. Tooth extractions may be necessary for a variety of reasons, such as pathologies of the pulp or periapex, periodontal disease, caries, pathologies like cysts, or teeth having fracture lines from trauma. Although dental extractions are typically regular and less invasive than other procedures offered in the specialty, problems after surgery can still occur.<sup>[4]</sup> Dental extraction-related post-operative complications might range from 0% to 35%.<sup>[5]</sup> Patients will experience several post-operative consequences, which can include hemorrhage, alveolar osteitis, paresthesia of the inferior alveolar nerve, post-operative pain, and infection.<sup>[6]</sup>

A dry socket, which typically manifests 2–4 days after surgery, is the most common post-operative complication after dental extraction.<sup>[7,8]</sup> Crawford, in 1876, was the first to elucidate about dry socket.<sup>[9]</sup> Other names for it include localized osteomyelitis, fibrinolytic alveolitis, septic socket, necrotic socket, alveolar osteitis, alveolalgia, and alveolitis sicca dolorosa.<sup>[7]</sup>

“Dry socket” colloquially describes a condition seen as a result of the absence of persistent blood clot or a layer of vital, persistent, healing epithelium within the socket and around its occlusal perimeter, and the bone within the socket or around that it is visible after the extraction.<sup>[10]</sup>

A blood clot could be disturbed by food debris that accumulates inside the extraction socket. The dry socket lesion may take longer to heal if food particles and bacterial biofilm hinder the repairing epithelium from touching the exposed bone. Bacteria can also cause fermentation of food particles inside the socket. This fermentation might produce toxins or antigens that might damage the exposed bone, result in halitosis or an unpleasant taste, and hurt the entire jaw. Evidence, however, indicates that dry socket may not be primarily caused by bacteria.<sup>[7]</sup>

## MATERIAL AND METHODS

### Sample design

From January 2021 to August 2022, patients treated in the Department of Oral and Maxillofacial Surgery (OMFS) at Sri Venkateshwara Dental College and Hospital made

up the cross-sectional study sample. Baseline information was gathered from databases of patients who had been diagnosed with dry socket and had been documented as part of standard case history recordings. The baseline data also included the COVID vaccination status and COVID history. Fifty patients, all of whom matched the inclusion criteria, were enrolled in the study.

### Study design

The demographic information was recorded as part of the customary case history paperwork when they visited the department of OMFS. Before performing the procedure, prophylactic antibiotics and analgesics were administered to symptomatic individuals. The surgical procedures were carried out in sterile conditions. Following the administration of the necessary nerve blocks, all extractions were carried out with the use of local anesthesia containing 2% lidocaine hydrochloride and 1:80,000 adrenaline. Whenever necessary, the surgical wounds were approximated using 3-0 silk sutures. After the surgery, the patients received comprehensive post-operative instructions as well as the appropriate analgesics and antibiotics. Follow-ups were conducted on a regular basis. All the patients who had post-surgical complications were thoroughly evaluated clinically and all the details were recorded in questionnaire format [Figures 1 and 2].

### Inclusion criteria

All of the study's participants, who ranged in age from 15 to 83 years, had either undergone surgical extractions or extractions of single or multiple teeth and who had returned with dry socket (Alveolar osteitis) with or without COVID-19 history or symptoms. These patients' follow-up sessions after the extraction surgery were further examined to gather information about their post-operative healing.

### Exclusion criteria

Every patient below 15 years of age and those without any post-operative complications, such as dry sockets, and those who did not undergo any extractions were eliminated from the study.

### Procedure

Before any procedures were undertaken, patients had their COVID-19 vaccination status checked, and they were asked to bring their COVID-19 test results. Age, gender, systemic medical history, COVID-19 history, site of extraction, type of extraction, and other characteristics including their adverse habit of the patients were recorded as variables in the study. Demographic baseline information and the patients' medical histories were all gleaned through case history recordings, as

NAME-

AGE-

SEX-

OCCUPATION-

OP NO-

PHONE NUMBER-

SYSTEMIC DISEASES-

- Diabetes
- Hypertension
- CNS
- CVS
- Blood dysfunction
- Drug allergy
- Any medication

ANY ADVERSE HABITS-

- Smoking
- Alcohol
- Tobacco chewing

ORAL HYGIENE STATUS-

VACCINATION STATUS-

- 1<sup>st</sup> DOSE
- 2<sup>nd</sup> DOSE
- PRECAUTIONARY DOSE

ANY COMPLICATIONS AFTER VACCINATION?

WHICH VACCINE HAD YOU TAKEN?

WERE YOU TESTED POSITIVE FOR COVID-19?

- Before or after vaccination?
- Before or after tooth extraction?

HOW DID YOU GET COVID? (1<sup>st</sup> Contact)-

DID YOU GET TESTED FOR COVID?

- RT-PCR
- RAPID ANTIGEN

WERE YOU SYMPTOMATIC OR ASYMPTOMATIC?

**Figure 1:** Questionnaire 1.

previously described. After clinical examination, the patients were instructed to get an intraoral periapical radiograph or orthopantomogram for better assessment. In addition, some individuals had systemic issues such as thyroid disorders, diabetes, hypertension, and asthma. Before the surgery, all of these patients were required to have their doctors' approval. Patients with diabetes were also counseled to undergo standard check-ups like random and fasting blood sugar tests.

The surgical site was checked for healing when the patients returned for regular follow-ups. Three days after surgery, the patient experienced acute pain that was unmanageable with analgesics and an empty, rancid-smelling socket with loss of the main sutures. Examination of infection and swelling, if present, revealed localized swelling in the surgical site which is tender with discharge happening 3–5 days after surgery. To obtain results for the research, each of these variables was meticulously examined and noted.

After receiving all the data, it was analyzed with the aid of descriptive analysis and inferential statistics using SPSS software. Chi-square test was also used to obtain relationship between the COVID-19 and alveolar osteitis.

IF SYMPTOMATIC, WHAT WERE THE SYMPTOMS?

DEGREE OF SEVERITY

- Mild
- Moderate
- Severe

WHAT MEDICATION HAD YOU TAKEN FOR COVID?

WERE YOU HOSPITALIZED?

NUMBER OF DAYS FOR RECOVERY FROM COVID

WHAT IS THE REASON FOR TOOTH EXTRACTION

WHICH TOOTH DID YOU GET IT EXTRACTED?

DID YOU APPLY ANYTHING ON THE SITE OR FACE FOR PAIN RELIEF (like amrutanjan, heat pack, hot water fomentation)

- Before extraction
- After extraction

WHEN DID YOU GET YOUR TEETH EXTRACTED?

WAS THERE ANY COMPLICATIONS DURING TEETH EXTRACTION?

(surgical extraction / Normal extraction / any trauma during extraction)

NUMBER OF INJECTIONS / BLOCKS GIVEN

WAS SUTURING DONE AFTER THE EXTRACTION?

WAS THERE ANY COMPLICATIONS AFTER EXTRACTION? (2-4 days after extraction)

- Pain-
- Swelling-
- Dryness-
- Delayed healing-

HOW WAS YOUR PROBLEM (DRY SOCKET/ANY OTHER) RESOLVED?

AFTER HOW MANY DAYS WAS IT RESOLVED?

**Figure 2:** Questionnaire 2.

## RESULTS

The study comprised 50 ( $n = 50$ ) individuals who underwent tooth extraction and then developed alveolar osteitis between January 2021 and August 2022.

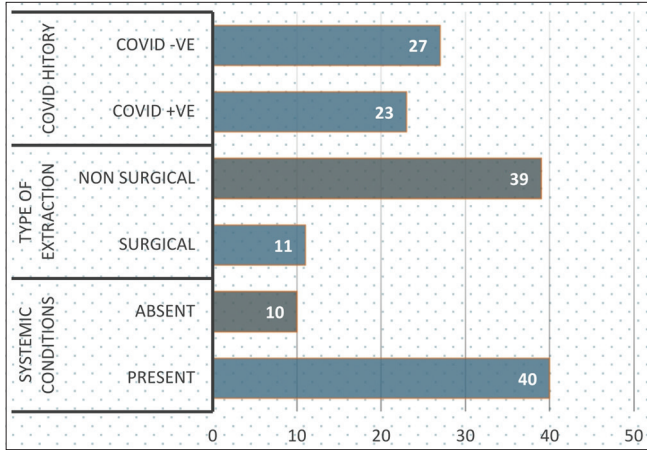
Of the 50 participants, more than half, that is, 27 (54%) did not present with a history of COVID-positive infection [Figure 3].

Among the 50 individuals that participated in the study, females were 31 (62%) and males were 19 (38%) [Figure 4].

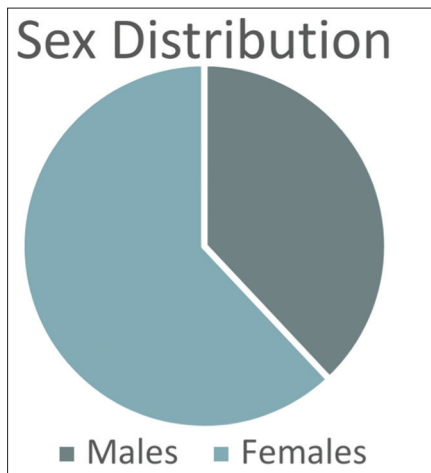
Participants in this study ranged in age from 15 to 83 years. Most patients belonged to the age group of 41–50 years (30%), followed by 31–40 years (20%) [Table 1 and Figure 5].

Many patients had systemic conditions such as thyroid disorders, diabetes, hypertension, and asthma. Among the participants, 40 (80%) cases had either of the above systemic conditions and 10 (20%) cases did not have any of the above systemic conditions [Figure 3].

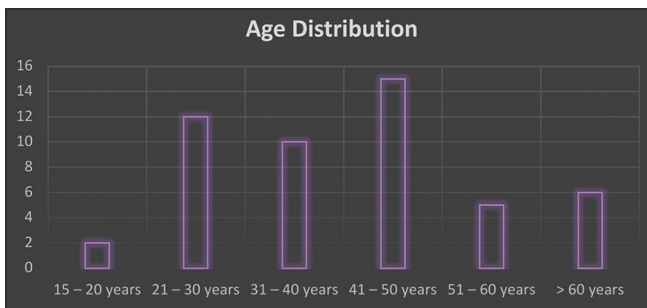
A small number of patients came to the department with a history of bad habits, such as smoking, chewing tobacco, paan, gutka, or betel nut, and drunkenness. Among 50 patients who had alveolar osteitis, 19 (38%) patients have a habit of smoking [Table 2], 21 (42%) patients have habit of tobacco use [Table 2], and 23 (46%) patients have habit of alcohol use.



**Figure 3:** COVID history, type of extraction, and systemic conditions.



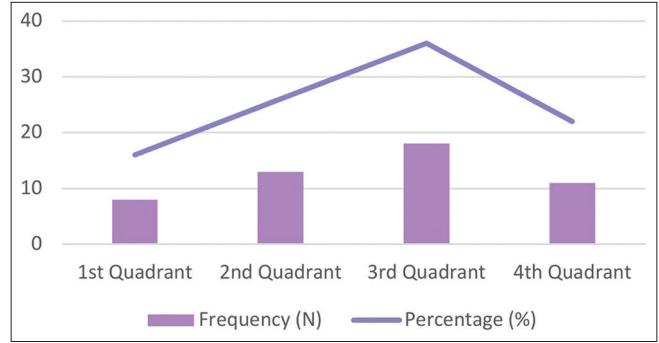
**Figure 4:** Sex.



**Figure 5:** Age.

Eighteen out of 50 cases of alveolar osteitis turned out to be present in 3<sup>rd</sup> quadrant, accounting for 36% of all cases, followed by 13 (26%) cases in 2<sup>nd</sup> quadrant. Eleven (22%) cases of alveolar osteitis were seen in 4<sup>th</sup> quadrant. Alveolar osteitis was seen only in 8 (16%) patients in 1<sup>st</sup> quadrant [Figure 6].

Eleven (22%) patients who had alveolar osteitis as a post-operative complication had undergone surgical extraction



**Figure 6:** Site of extraction.

**Table 1:** Distribution of study participants according to age.

Age group	Frequency	Percentage
15–20 years	2	4
21–30 years	12	24
31–40 years	10	20
41–50 years	15	30
51–60 years	5	12
>60 years	6	10
Total	50	100

and 39 (78%) patients had undergone simple/non-surgical extraction [Figure 3].

Majority of the COVID-negative patients with alveolar osteitis that is 36% were non-smokers. No statistically significant relation was observed in patients with alveolar osteitis who had a history of smoking and previous COVID history ( $P > 0.05$ ) [Table 2].

Most of the COVID-negative patients with alveolar osteitis that is 32% have no habit of chewing tobacco. No statistically significant relation was observed in patients with alveolar osteitis who has the habit of chewing tobacco and previous COVID history ( $P > 0.05$ ) [Table 2].

Majority of the COVID-negative patients with alveolar osteitis that is 42% have no habit of alcohol use. No statistically significant relation was observed in patients with alveolar osteitis who has the habit of alcohol consumption and previous COVID history ( $P > 0.05$ ) [Table 2].

Among 50 cases of dry socket, 22 (44%) of cases with either of the above systemic conditions had a positive COVID history. Statistically, there was a significant relationship between patients with alveolar osteitis who had COVID-positive history and has any underlying mentioned systemic conditions  $P = 0.014$  ( $P \leq 0.05$ ) [Table 3].

Among 50 patients, 20 cases, that is, 40% of alveolar osteitis were seen in non-COVID patients who had undergone simple/non-surgical extraction of the tooth. No statistically significant relation was observed in patients with alveolar



osteitis who had previous COVID history and type of extraction ( $P > 0.05$ ) [Table 4].

## DISCUSSION

In Wuhan, China, there was an epidemic that gave rise to the coronavirus pandemic. December 2019 through the start of 2020, the coronavirus, which is an infectious disease, spread quickly around the world. It has not only had a negative impact on people's physical health but also significantly

affected their mental health, oral health, and the degree of "health anxiety" they may experience.<sup>[11]</sup>

COVID-19's oral manifestation includes – xerostomia, halitosis, parotitis, sialadenitis, and taste disorders such as dysgeusia, hypogeusia, and ageusia. The most frequent oral lesion was an aphthous-like oral ulcer. Herpes-like lesions, candidiasis, glossitis, depapillation, geographic tongue, parotitis, and angular cheilitis were next.<sup>[12]</sup>

Patients will experience several post-operative consequences, which can include hemorrhage, alveolar osteitis, inferior alveolar nerve paresthesia, post-operative discomfort, and infection. Alveolar osteitis was the most frequent post-surgical consequence.

The purpose of this research was to ascertain the inter-relation of the occurrence of alveolar osteitis in patients during the follow-up recall after the surgical procedures in COVID-19 situation.

### Alveolar osteitis

According to researchers, the following defines a dry socket: "post-operative pain surrounding the alveolus that increases in severity for some period from 1 to 3 days after extraction, followed by partial or total clot loss in the interior of the alveolus, with or without halitosis."<sup>[7,13]</sup>

Alveolar osteitis was initially identified as a side effect of breakdown in the blood clot inside the socket, which manifested 2–4 days following tooth removal.<sup>[14]</sup> The surrounding mucosa typically turns erythematous, the alveolus empties, and the osseous surrounds are denuded and covered in a layer of yellow-grey necrotic tissue, claim Fazakerlev and Field.<sup>[15]</sup> Clinically, it is distinguished by a foul smell and severe discomfort that extends to the ear and neck.<sup>[16]</sup> Pain is the most significant indication of alveolar osteitis. Other symptoms including headache, insomnia, and dizziness may also exist, and its frequency and intensity can vary.<sup>[17]</sup>

Bone that is exposed and extremely painful to touch may not be protected from mechanical stimulation either by tongue or food particles, leaving the patient in constant, and excruciating pain. All areas of a dry socket lesion, excluding the exposed bone, can be delicately touched with an irrigation needle tip or periodontal probe without causing excruciating discomfort.

Dry socket is generally characterized as "an inflammation in the alveolus of recently extracted teeth, for which discomfort and the time of onset are particular clinical indicators indicative of accurate diagnosis."

When viewed under a microscope, a dry socket is defined by an inflammatory cellular infiltrate, which includes numerous giant cells and phagocytes in the blood clot, along with the presence of bacteria and necrosis of the lamina dura.<sup>[18]</sup>

**Table 2:** Association between COVID history and adverse habits.

	COVID History			Chi-square*	P-value*
	Present n	Absent n	Total		
Smoking					
Present	10	9	19	0.543	0.563
Absent	13	18	31		
Total	23	27	50		
Tobacco					
Present	10	11	21	0.038	1.000
Absent	13	16	29		
Total	23	27	50		
Alcohol					
Present	8	6	14	0.972	0.361
Absent	15	21	36		
Total	23	27	50		

\*Chi-square test, \*Level of significance at  $P \leq 0.05$

**Table 3:** Association between COVID history and systemic conditions.

	COVID History			Chi-square*	P-value*
	Present n	Absent n	Total		
Systemic conditions					
Present	22	18	40	6.522	*0.014
Absent	1	9	10		
Total	23	27	50		

\*Chi-square Test, \*Level of significance at  $P \leq 0.05$ . A statistically significant association was seen between history of covid-19 patients and systemic condition.

**Table 4:** Association between COVID history and type of extraction.

	COVID History			Chi-square*	P-value*
	Present n	Absent n	Total		
Type of extraction					
Surgical	4	7	11	0.527	0.515
Simple/ Non-surgical	19	20	39		
Total	23	27	50		

\*Chi-square test, \*Level of significance at  $P \leq 0.05$

## Etiology and pathophysiology of dry socket

Dry socket's precise cause is not yet known. However, it is known that a number of regional and systemic factors play a role. Dry socket occurs when the clot inside the socket following tooth removal prematurely dissolves, either completely or partially increased local fibrinolytic activity has been identified in clinical and experimental research as a key component in the formation of dry socket.<sup>[19,20]</sup>

When compared to a normal alveolus, Birn found that the alveolus with a dry socket had more fibrinolytic activity. He emphasized that plasminogen's direct or indirect activation into the bloodstream produces mediators that cause the partial or whole lyse and disintegration of the clot.<sup>[19]</sup> After a trauma, the alveolar bone cells release mediators that cause plasminogen to be transformed into plasmin, which ruptures clots by forcing fibrin to disintegrate. This conversion takes place in the presence of additional activators as well as plasmatic or cellular proactivators. The recent classification includes direct (physiologic) and indirect (non-physiologic), as well as subclassifications based on their origins as intrinsic or extrinsic activators.<sup>[21]</sup>

Intrinsic factors, such as urokinase and factor XII-dependent or Hageman factor, are derived from plasma components. In contrast, direct extrinsic activators, which also include tissue and endothelial plasminogen activators, come from sources other than the plasma. Tissue plasminogen activators are present in the majority of body cells, including the alveolar bone. The bacterial products staphylokinase and streptokinase, which interact with plasminogen to generate an activator complex that transforms plasminogen into plasmin, are among the indirect activators.<sup>[21]</sup>

Kinins that form in the alveolus are regarded as the root of the common alveolar osteitis pain. The primary bundles of nerve terminations are stimulated by kinins, which may already be responsive to different proinflammatory cytokines and chemicals that produce excruciating pain. In addition, kallikrein is transformed into kinins by plasmin inside the marrow. Hence, the important elements of dry socket could be explained by the presence of plasmin.

Dry socket has also been linked to surgical extractions, particularly those involving flaps and tooth sectioning with an osteotomy level.<sup>[22]</sup>

Another potential cause of dry socket is the socket's inclusion of bone and dental remains.<sup>[23]</sup>

In experimental dry socket models, a variety of bacteria were found in the biologic material of the alveolus, including *Strep viridians*, *Enterobacteria*, *Bac. coryneform*, *Proteus vulgaris*, *Pseudomonas aeruginosa*, and *Escherichia coli*.<sup>[24]</sup> At infancy, when these microorganisms are typically undetectable in the oral environment, dry socket is a rare occurrence.

Smoking is another trigger for dry socket occurrence.<sup>[25]</sup> In 1999, Monaco *et al.* discovered a statistically significant correlation between risky behaviors including smoking and alcohol consumption and difficulties following surgery, such as discomfort and illness.<sup>[26]</sup> In addition, higher frequency of alveolar osteitis was noted in individuals who were above the age of 18 years. Furthermore, aging was a risk factor, in which other researchers have previously noticed.<sup>[27]</sup>

## Effect of COVID-19 on vascularity

Blood vessel endothelium experiences an inflammatory immunological reaction known as endotheliitis. According to many reports, histological examination and electron microscopy of individuals who died from COVID-19 revealed a build-up of viral inclusions and inflammatory cells.<sup>[28]</sup>

A systemic inflammatory response must be triggered by SARS-CoV-2's ability to infect cells of blood vessels and cause a severe inflammatory response locally. Some publications have compared the symptoms of SARS-CoV-2's systemic inflammation to those of a cytokine storm. This cytokine storm further leads to disseminated intravascular coagulation which has also been detected in COVID-19 infections, but typically in the patients who are seriously unwell.<sup>[29]</sup>

Commonly encountered coagulation abnormalities in COVID-19 patients point to a hypercoagulable condition known as COVID-associated hemostatic abnormalities or thromboinflammation.<sup>[30,31]</sup> Elevation of D-dimer is a prevalent finding in patients suffering from COVID-19, especially those who have severe disease.<sup>[32]</sup> D-dimer forms as a result of the breakdown of fibrin; its presence in the bloodstream indicates that plasmin is breaking down fibrin polymers, and it may be related to the burden of thrombi.

The authors identified hypercoagulability characteristics using whole blood thromboelastography, including a decline in the duration required for fibrin to develop, a reduction in the time it takes for clots to form, and an increase in coagulation strength.<sup>[33]</sup>

## Effect of COVID-19 on bone

By potentially invading the bone cells (osteoblasts and osteoclasts) and interfering with the bone remodeling process, SARS-CoV-2 has the ability to infect the skeletal system. Beside the inflammatory potential, angiotensin converting enzyme 2 (ACE-2)/Angiotensin (1-7) axis has been identified as being linked with osteoporosis, which is indicated by the action of ACE-2 receptors on osteoblasts and osteoclasts.<sup>[34]</sup>

The vast majority of patients who were older than 35 reported having dry sockets. Several patients arrived at the hospital in great discomfort, and a dry socket diagnosis was made

during the inspection. Several individuals disclosed a habit of tobacco smoking as well as hyperglycemia as well as other systemic diseases. Several studies have shown a strong connection between smoking, alveolar osteitis, and diabetes. While there is a general immune system deficit that may have hampered the tissue regeneration, it was found in our study that there was a strong link between individuals suffering from systemic illnesses and COVID-19 history of alveolar osteitis, or diabetes.

As a result, cigarette smoke has chemical irritants that can slow tissue regeneration. Dry socket may be averted by abstaining from smoking, adhering to post-operative guidelines, and practicing good dental hygiene as well as by administering antibiotic therapy to diabetic patients before surgery.

All patients with dry socket were treated by thorough curettage, betadine irrigation followed by betadine ointment pack. All patients received the necessary prescriptions for betadine mouthwash, analgesics, and antibiotics. After 2 weeks of follow-up, the inflammation and infections were under control.

This study's primary flaw is its extremely tiny sample size, which makes it challenging to draw any relationships or draw any conclusive evidence. The study's findings are appropriate for this topic, nevertheless due to the study's small sample size, they cannot be generalized to the total population.

## CONCLUSION

Remarkable correlation was seen between patients who had systemic conditions and COVID-positive history with alveolar osteitis. Alveolar osteitis had a significant predilection toward females. All of the cases of alveolar osteitis that was seen had a solid history of smoking or paan chewing, suggesting a substantial link with habit history and the condition. No statistically significant variation was detected in the patients who had COVID history and habit history with alveolar osteitis. However, COVID-19 and alveolar osteitis were not correlated in all the variables such as type of extraction, site of extraction, and habit history, but it was correlated in the patients with systemic conditions. It is interesting to note that every patient who reported of a dry socket also had other systemic conditions such as diabetes, hypertension, and thyroid disorders. Antibiotics and analgesics were administered as preventative measures to each subject in our study. The lower incidence of problems may be explained by the fact that the procedures were carried out under aseptic settings by experienced oral surgeons.

## Acknowledgment

We appreciate the help that we received from the Oral and Maxillofacial Surgery team as they guided us through the

procedure. We also gratefully appreciate the help with the collection of data and tabulation provided by the juniors and residents in the department of oral and maxillofacial surgery.

## Declaration of patient consent

Patient's consent not required as patients identity is not disclosed or compromised.

## Financial support and sponsorship

Nil.

## Conflicts of interest

There are no conflicts of interest.

## REFERENCES

- Dziedzic A, Wojtyczka R. The impact of coronavirus infectious disease 19 (COVID-19) on oral health. *Oral Dis* 2021;27(Suppl 3):703-6.
- Zhou M, Zhang X, Qu J. Coronavirus disease 2019 (COVID-19): A clinical update. *Front Med* 2020;14:126-35.
- Dong E, Du H, Gardner L. An interactive web-based dashboard to track COVID-19 in real time. *Lancet Infect Dis* 2020;20:533-4.
- Patel S, Koshal S, Mudhar O. The impact of COVID 19 on oral surgery post-operative patient complications and communications within the oral surgery department at the Eastman dental hospital. *Eur J Dent Oral Health* 2021;2:8-11.
- Dallaserra M, Poblete F, Vergara C, Cortés R, Araya I, Yanine N, *et al.* Infectious postoperative complications in oral surgery. An observational study. *J Clin Exp Dent* 2020;12:e65.
- Rakhshan V. Common risk factors for postoperative pain following the extraction of wisdom teeth. *J Korean Assoc Oral Maxillofac Surg* 2015;41:59-65.
- Blum IR. Contemporary views on dry socket (alveolar osteitis): A clinical appraisal of standardization, aetiopathogenesis and management: A critical review. *Int J Oral Maxillofac Surg* 2002;31:309-17.
- Turner PS. A clinical study of "dry socket". *Int J Oral Surg* 1982;11:226-31.
- Crawford JY. Dry socket. *Dent Cosmos* 1896;38:929-31.
- Bowe DC, Rogers S, Stassen LF. The management of dry socket/alveolar osteitis. *J Ir Dent Assoc* 2011;57:305-10.
- Qiu J, Shen B, Zhao M, Wang Z, Xie B, Xu Y. A nationwide survey of psychological distress among Chinese people in the COVID-19 epidemic: Implications and policy recommendations. *Gen Psychiatr* 2020;33:e100213.
- Dos Santos JA, Normando AG, da Silva RL, Acevedo AC, De Luca Canto G, Sugaya N, *et al.* Oral manifestations in patients with COVID-19: A living systematic review. *J Dent Res* 2021;100:141-54.
- Torres-Lagares D, Serrera-Figallo MA, Romero-Ruiz MM, Infante-Cossío P, García-Calderón M, Gutiérrez-Pérez JL. Update on dry socket: A review of the literature. *Med Oral Patol Oral Cir Bucal* 2005;10:77-85.

14. Noroozi AR, Philbert RF. Modern concepts in understanding and management of the “dry socket” syndrome: Comprehensive review of the literature. *Oral Surg Oral Med Oral Pathol Oral Radiol Endod* 2009;107:30-5.
15. Fazakerlev M, Field EA. Dry socket: A painful post-extraction complication (a review). *Dent Update* 1991;18:31-4.
16. Swanson AE. A double-blind study on the effectiveness of tetracycline in reducing the incidence of fibrinolytic alveolitis. *J Oral Maxillofac Surg* 1989;47:165-7.
17. Sasaki T, Okamoto T. Topical treatment of infections of alveolar socket infections following dental extraction. *Rev Bras Odontol* 1968;25:82-92.
18. Faillo PS. Proteolytic enzyme treatment for the necrotic alveolar socket (dry socket). *Oral Surg Oral Med Oral Pathol* 1948;1:608-13.
19. Birn H. Etiology and pathogenesis of fibrinolytic alveolitis (“dry socket”). *Int J Oral Surg* 1973;2:211-63.
20. Birn H. Bacteria and fibrinolytic activity in “dry socket”. *Acta Odontol Scand* 1970;28:773-83.
21. Vezeau PJ. Dental extraction wound management: Medicating postextraction sockets. *J Oral Maxillofac Surg* 2000;58:531-7.
22. Lilly GE, Osbon DB, Rael EM, Samuels HS, Jones JC. Alveolar osteitis associated with mandibular third molar extractions. *J Am Dent Assoc* 1974;88:802-6.
23. Simpson HE. The healing of extraction wounds. *Br Dent J* 1969;126:550-7.
24. De Melo JE, Raposo MJ, Lisboa Neto JA, Diniz MF, Marcelino Júnior CA, Sant’Ana AE. Medicinal plants in the healing of dry socket in rats: Microbiological and microscopic analysis. *Phytomedicine* 2002;9:109-16.
25. Sweet JB, Butler DP. The relationship of smoking to localized osteitis. *J Oral Surg* 1979;37:732-5.
26. Monaco G, Staffolani C, Gatto MR, Checchi L. Antibiotic therapy in impacted third molar surgery. *Eur J Oral Sci* 1999;107:437-41.
27. Chiapasco M, Crescentini M, Romanoni G. The extraction of the lower third molars: Gernectomy or late avulsion? *Minerva Stomatol* 1994;43:191-8.
28. Sharma A, Garcia G Jr., Wang Y, Plummer JT, Morizono K, Arumugaswami V, *et al.* Human iPSC-derived cardiomyocytes are susceptible to SARS-CoV-2 infection. *Cell Rep Med* 2020;1:100052.
29. Tang N, Li D, Wang X, Sun Z. Abnormal coagulation parameters are associated with poor prognosis in patients with novel coronavirus pneumonia. *J Thromb Haemost* 2020;18:844-7.
30. Connors JM, Levy JH. Thromboinflammation and the hypercoagulability of COVID-19. *J Thromb Haemost* 2020;18:1559-61.
31. Thachil J, Cushman M, Srivastava A. A proposal for staging COVID-19 coagulopathy. *Res Pract Thromb Haemost* 2020;4:731-6.
32. Richardson S, Hirsch JS, Narasimhan M, Crawford JM, McGinn T, Davidson KW, *et al.* Presenting characteristics, comorbidities, and outcomes among 5700 patients hospitalized with COVID-19 in the New York City area. *JAMA* 2020;323:2052-9.
33. Wright FL, Vogler TO, Moore EE, Moore HB, Wohlauer MV, Urban S, *et al.* Fibrinolysis shutdown correlation with thromboembolic events in severe COVID-19 infection. *J Am Coll Surg* 2020;231:193-203.e191.
34. Queiroz-Junior CM, Santos AC, Galvão I, Souto GR, Mesquita RA, Sá MA, *et al.* The angiotensin converting enzyme 2/angiotensin-(1-7)/Mas receptor axis as a key player in alveolar bone remodelling. *Bone* 2019;128:115041.

**How to cite this article:** Nishanth MS, Vishwas L, Tantry D. Is alveolar osteitis more prevalent since COVID-19? A cross-sectional study. *J Academy Dent Educ* 2023;9:5-12.