

Potential Morbidities of Dental Infections

C. Preetha¹ and A. Narendran²

¹Intern; ²Senior Lecturer, Department of Oral And Maxillofacial Surgery, Vinayaka Mission's Sankarachariyar Dental College, NH - 47 main road, Ariyanoor, Salem - 636308, Tamil Nadu, India; principal.vmsdc@vmu.edu.in

Date of Receiving: June 2016

Date of Submission: July 2016

Date of Acceptance: Oct 2016

Abstract

With the advent of antibiotics and the improved dental care there is decreasing incidence of odontogenic space infections. But with delayed treatment, they present challenging problems and potentially life threatening situations.

Keywords: Fascial spaces, Pathogenic microorganisms, Spread of infection, Potential morbidities.

1. Introduction

Maxillofacial infections are the common problem encountered by the oral surgeons. They present a risk to patients regardless of the origin i.e., odontogenic or non odontogenic. Fascial spaces readily break down when invaded by pathogenic micro-organisms. Most of the anatomic spaces of head and neck region have communication with each other, and when there is an imbalance between the bacterial virulence and patient's immune system, infections set in and spread from one region to another. Regardless of the source of infection, the general clinical symptoms are similar with clinical manifestations specific to the space involved. Herewith, presenting a series of various space infection cases occurring most common to rare of its kind.

2. Series of Space Infection Cases

Common space infections encountered in dental practice

3. A Rare Case where Multiple Spaces were involved Due to Odontogenic Etiology

A 49 year old male patient named Ram reported to the dental OP with difficulty in mouth opening, severe pain and pus discharge in the left lower back teeth. Patient was

apparently normal 20 days before presenting to the OP and he had undergone extraction of 37.

On clinical examination, patient had multiple swellings in the head and face region, involving the buccal space, infratemporal and the occipital region (Figure 2(a)). On inspection patient had an swelling extending from the floor of the orbit to the lower border of the mandible and 2 mm away from the ala of the nose till 1 mm away from the tragus of the ear. On palpation, the swelling was soft and fluctuant, tender on palpation and the skin over the swelling was normal. Patient had restricted mouth opening (Figure 2(b)). Intraorally patient had pus discharge in the extracted socket in relation to 37. There was also separate swellings present in the infratemporal and the occipital region which was soft and fluctuant.

Patient was diagnosed with multiple space infection and the CT scan (Figure 2(c)) revealed spread of infection in the occipital region and soft tissue expansion along the left side. Patient was treated by incision and drainage under general anesthesia (Figure 2(d)) and antibiotic regimens were given. Patient's recovery was satisfactory (Figure 2(e)). The pus culture report revealed the presence of *Candida albicans*.

4. Discussion

4.1 Classification of Fascial Spaces

- Based on mode of involvement.

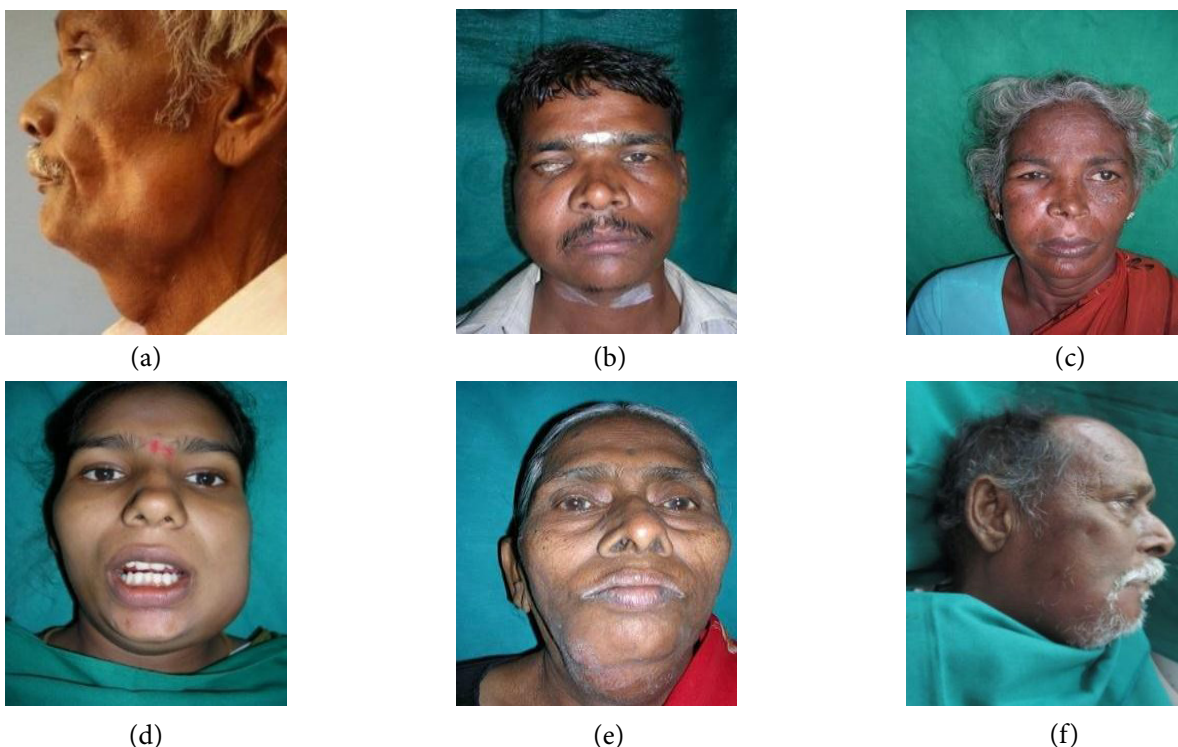

Figure 1. (a) A case with dentoalveolar abscess. (b) A case with buccal space infection. (c) A case with canine space infection. (d) A case with submassetric common space infection. (e) A case with submandibular space infection. (f) A case with submental and submandibular space infections.

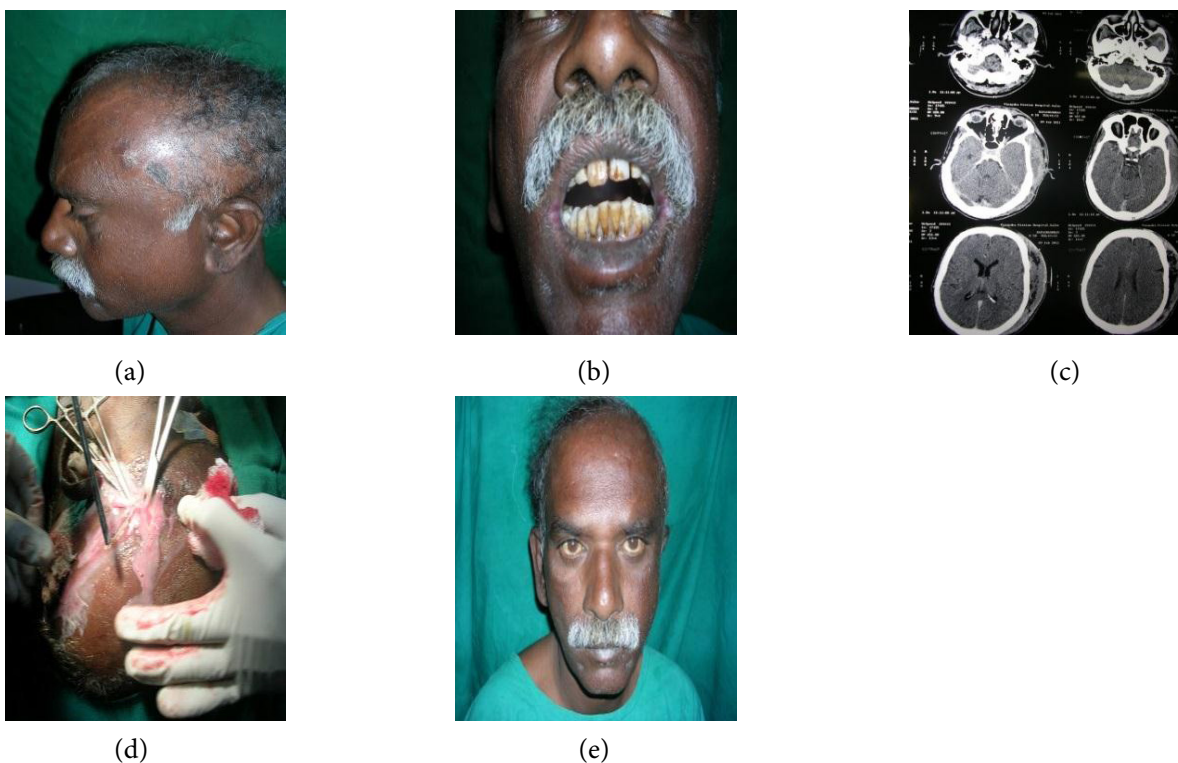


Figure 2. (a) Buccal, infratemporal and occipital space infections. (b) Limited mouth opening. (c) CT scan report. (d) During incision and drainage. (e) Post operative photograph.

- Based on clinical significance.

4.1.1 Based on Mode of Involvement

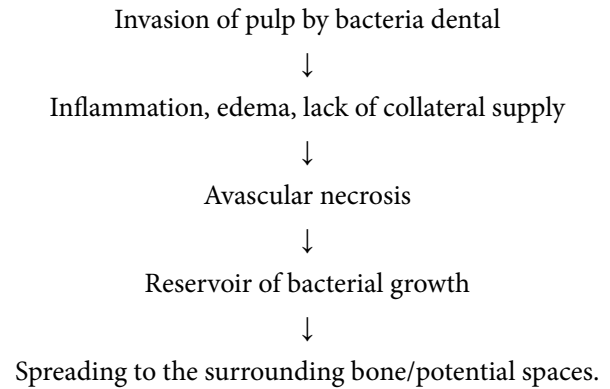
4.1.1.1 Primary Spaces

Primary maxillary spaces: Canine, buccal, infratemporal
 Primary mandibular spaces: Submental, sublingual, buccal, submandibular.

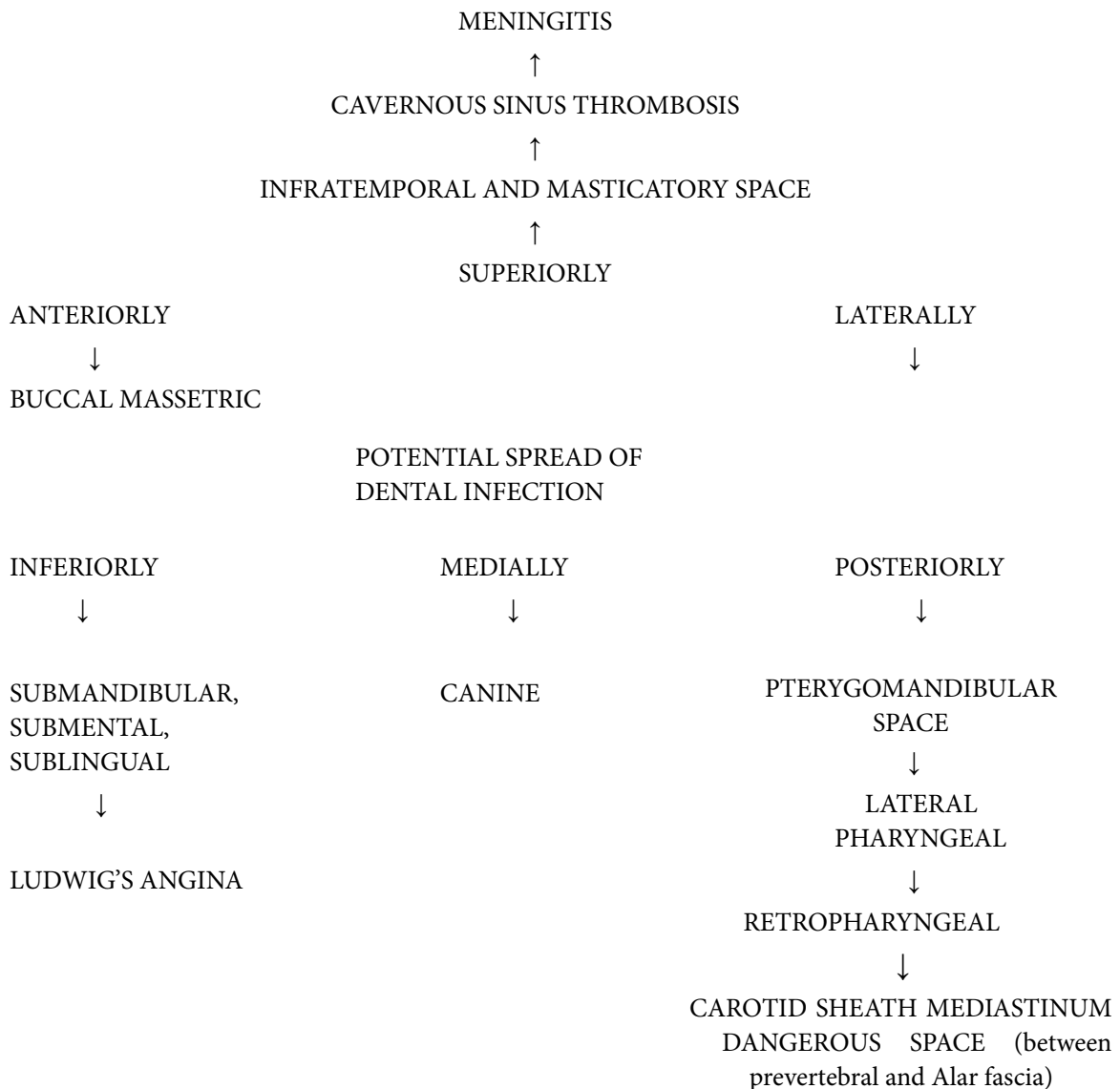
4.1.1.2 Secondary Spaces

Masseteric, pterygomandibular, superficial and deep temporal, lateral pharyngeal, retropharyngeal, parotid, prevertebral.

PATHWAY OF ODONTOGENIC INFECTION:



COMMUNICATION OF FASCIAL SPACES



4.2 Based on Clinical Significance

Face- Buccal, canine, parotid, masticatory

Suprahyoid- Sublingual, submental, submandibular, lateral pharyngeal, peritonsillar Infrahyoid – Pretracheal

Spaces of total neck – Retropharyngeal, space of carotid sheath

Most odontogenic infections arise as sequelae of pulpal necrosis. The seriousness of an infection beyond the apex of a tooth is related to the number and virulence of the microorganisms, host resistance and associated anatomic structures. Once the infection has spread beyond the tooth socket, it may localize or continue to spread through bone and soft tissue as a diffuse abscess or cellulitis involvement of the potential fascial spaces.

5. Conclusion

Oral and maxillofacial infections, which are commonly encountered by the oral surgeons, are caused by both aerobic and anaerobic organisms. Of the series of space infection cases we came across, the commonly involved space was buccal space infection followed by masseteric, canine and submandibular space infections. And the common organism involved was staphylococcus aureus.

But the multiple space infection case result was candida albicans. Hence it is mandatory to know the organism and treat the space infection cases with proper antibiotic regimen active against the organisms involved and understanding the importance of the role played by the patient's immune system in the spread of infection is of great importance.

6. References

1. Gilly Y, Scully C. Orofacial odontogenic infections. Review of microbiology and current treatment. *Oral Surgery, Oral Medicine, Oral Pathology*. 1990 Aug; 70(2):155–8.
2. Topazian. *Book of oral and maxillofacial infections*. 4th 2002 ed.
3. William S, Richard H, Thomas TL. The changing face of odontogenic infection. *J Oral Maxillofac Surg*. 2001; 59:739–48.
4. Daniel L, Mascaro, Brian A. The Microbiologic Flora Of Orofacial Abscesses. *J Oral Maxillofac Surg*. 1983; 41:711–4.
5. Iatrou A. Anaerobic bacteria in jaw cysts. *BJOMS*. 1988.
6. William Storoe. The changing face of odontogenic infections. *J oral and maxillofac surg*. 2001 Jul; 59(7):739–48.
7. Peters ES. Risk factors affecting hospital length of stay in patients with odontogenic maxillofacial infections. *J oral and maxillofac surg*. 1996 Dec; 54(12):1386–91.