

Effects of Coconut and Olive Oil on Tooth and Restoration – in vitro Study- Myth(oil)ogy?

Vanashri Saravanan¹, Vaanishree M. Kumar¹, A. Thentamil² and Mathew Jacob³

¹Student; ²Lecturer, Department of Oral Biology, Penang International Dental College, NH-47, Sankari Main Road, Veerapandi Post, Salem – 636308, Tamil Nadu, India; sam@pidc.edu.my

³Reader, Department of Oral Pathology, Vinayaka Mission's Sankarachariyar Dental College, NH-47, Sankari Main Road, Ariyanoor, Salem – 636308, Tamil Nadu, India; principal.vmsdc@vmu.edu.in

Abstract

One of the natural and traditional methods adopted for obtaining whiter teeth is oil pulling. This is a simple and cost efficient method which has been used for decades and advised for overall maintenance of oral hygiene. However, there have been contradicting results regarding the efficacy of oil pulling on tooth whitening in previous studies. In this study, natural teeth (premolar teeth) were collected and divided into four groups and preserved in different mediums for 24 hours for a period of seven days to study the effects on hard tissue enamel. The teeth were observed every 24 hours and the difference in tooth whitening was compared using a tooth shade guide and evaluated for observable changes in colour.

Keywords: Acrylic Tooth, Coconut Oil, Lime Juice, Olive Oil, Premolars, Shade Guide, Whitening Paste

Date of Receiving: October 2018

Date of Submission: December 2018

Date of Acceptance: December 2018

1. Introduction

With the sudden surge in the internet, several websites and forums have “reintroduced” or advocated oil pulling as a traditional and natural remedy to obtain whiter teeth. Oil pulling or oil swishing, is an ancient Ayurvedic procedure that involves swishing oil in the mouth for oral and systemic health benefits. Oil pulling benefits by improving the physiological functioning of the cells of the immune system. In relation to oral hygiene, oil pulling particularly with extra virgin coconut oil has been known to have a whitening effect on teeth. The present study attempts to investigate the effects of oil (simulating the physical and chemical effect of oil pulling) on the teeth.

2. Aim

The aim of this study is to observe the effects of various types of oil on the whitening of premolars by comparing the changes in the colour of the teeth over a period of 7 days with a tooth shade guide.

3. Objectives

- To study the effect of two natural oils (coconut and olive oil) on the tooth after the preservation in coconut and olive oil by inspecting every 24 hours for a period of seven days.
- To study the effect of lime juice and commercially available whitening paste on the tooth after the preservation in respective medium by inspecting every 24 hours for a period of seven days.
- To study the effects of two natural oils (coconut and olive oil) on tooth coloured restorative material, Glass Ionomer Cement after the preservation in respective medium by inspecting every 24 hours for a period of seven days.
- To study the cumulate effect of oil/media at the end of the 7 days using tooth shade guide (Vita 3D – model).

4. Methodology

Recently extracted premolars were collected from private clinics for this study. All the collected teeth were cleaned

with a brush and toothpaste and preserved in saline till the time of study. Premolars with any extrinsic stain or developmental anomalies of the hard tissue were excluded from the study. Prior to the preservation in oil/medium, the teeth were rinsed with distilled water and wiped with gauze to remove any debris and the colour (shade) of the teeth was recorded. Root apex of each tooth was sealed with composite resin to prevent the permeability of the oil/medium through the apical foramen. Also, to study the effects of oil/medium on tooth coloured restorative material, a round cavity with depth of 1 mm was prepared with a straight fissure bur on the buccal aspect of four premolars and Glass Ionomer Cement (GIC) restorative material was used to fill the cavity.

4.1 Selection Criteria of Tooth

- Premolars were selected for this experiment (extracted for the purpose of orthodontic treatment).
- Non-carious.
- Intact crown without any restoration.
- Teeth without any resorption or extrinsic stains.

4.2 Preservation in Oil/Medium

In this study, 12 natural premolar teeth were divided into 4 groups and preserved in oil/medium. In each medium, 3 natural teeth (with apex sealed with composite) and 1 acrylic tooth were preserved;

- N1 - Natural Premolar tooth.
- N2 - Natural Premolar tooth with GIC restoration on buccal side.
- N3 - Natural Premolar tooth with cervical 2/3rd of the crown sealed (2-3layers of fevicol and transparent nail polish were applied using a paint brush).
- N4 - Acrylic tooth – Incisor.

On day 0 of the study, photographs of all the teeth placed on a black chart paper (as background) were taken in a well-lit area using a Digital camera of resolution of 12 megapixels (12MP). The before or initial colour of the crown of the natural teeth and the acrylic were recorded using a shade guide (Figure 1, 2, 3, 4).

A sterile airtight container was used to preserve the teeth in 10 ml of each medium. The oils used in the study were the commercially available coconut and olive oil. The oil/medium were labelled as M1 to M4.

Medium 1-M1 - Coconut oil.

Medium 2-M2 - Lime juice diluted with 5ml of water.

Medium 3-M3 - Olive oil.

Medium 4-M4 - For positive control, commercially available whitening toothpaste was applied on each tooth using a new toothbrush every 24 hours.




Figure 1. Teeth preserved in coconut oil, M1 (from left to right- tooth shade guide, N1, N2, N3, N4, Shade guide).

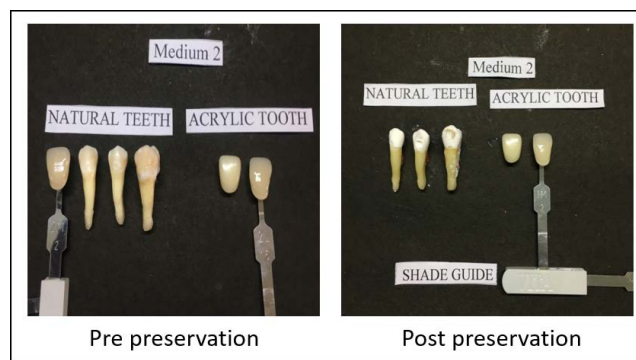


Figure 2. Teeth preserved in diluted lime juice, M2 (from left to right- tooth shade guide, N1, N2, N3, N4, Shade guide).

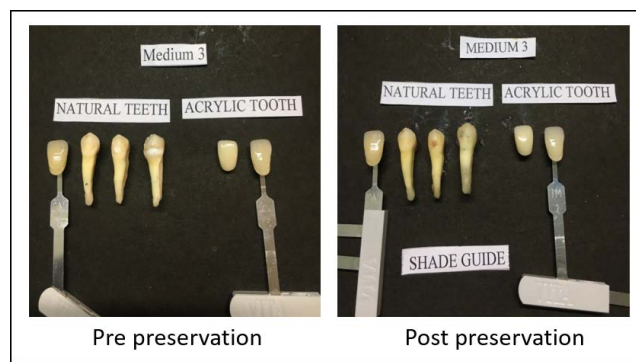


Figure 3. Teeth preserved in olive oil, M3 (from left to right- tooth shade guide, N1, N2, N3, N4, Shade guide).

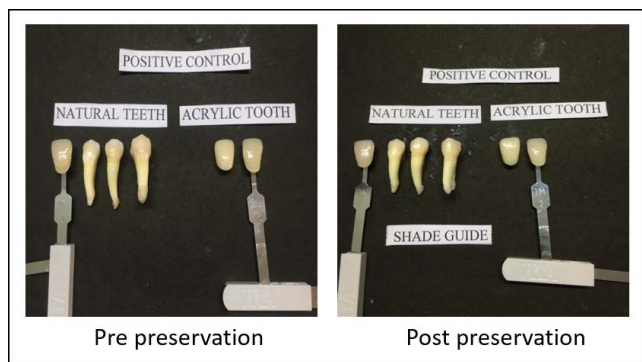


Figure 4. Teeth preserved in coconut oil, M4 (from left to right- tooth shade guide, N1, N2, N3, N4, Shade guide).

The teeth were left in the medium for 24 hours, and then all the teeth were rinsed with distilled water and the medium was replaced with another 10ml at the end of the 24 hours. This procedure was repeated for six consecutive days for a total of seven days.

On the 7th day of the study, all the teeth were removed from the sterile airtight container and cleaned with a new toothbrush to remove all oil/medium on the tooth sur-

face. Post preservation photographs of all the teeth were taken on a black chart paper background in a well-lit area with the same Digital camera of 12MP resolution. The final colour of the crown of the natural teeth and acrylic teeth were recorded using a shade guide. And the changes to the GIC restoration as well as changes between the sealed cervical 2/3rd of the crown and the unsealed 2/3rd of the crown were noted as well (Figure 1, 2, 3, 4).

4.3 Blind Observer Recording

To obtain unbiased observation to the changes on the natural tooth, four students from first year undergraduate dental students were selected (not part of the procedure/study) and were showed the pre and post preservation photographs of the tooth. The observations are given in Table 1.

5. Results

The results and inferences of the study are given in Tables 2, 3. The findings have given based on the actual changes and are given as positive (PF) and negative findings (NF).

Table 1. Observations recorded (I Year undergraduate dental students)

M 1 – Coconut oil				
Observer	Visible changes (Yes/no)	Mild	Moderate	Highly observable
1	Yes	-		-
2	Yes	-		-
3	Yes		-	-
4	Yes	-		-
M 2 – Lime juice				
1	Yes	-	-	Chalky white
2	Yes	-	-	Chalky white
3	Yes	-	-	Chalky white
4	Yes	-	-	Chalky white
M 3 – Olive oil				
1	No	-	-	-
2	No	-	-	-
3	No	-	-	-
4	No	-	-	-
M 4 – Whitening paste				
1	Yes	-		-
2	Yes	-	-	
3	Yes		-	-
4	Yes		-	-

Table 2. Observations recording changes in colour using tooth shade guide

MEDIUM	PRE PRESERVATION (SHADE)	POST PRESERVATION (SHADE)	CHANGES OBSERVED
Changes in shade of natural tooth (N1)			
M 1	2M3	2M2	One shade lighter (PF)
M 2	2M2	Chalky white	Chalky white (NF)
M 3	2M3	2M3	No changes (NF)
Positive Control	2M2	2M1	One shade lighter (PF)
Changes in shade of acrylic tooth (N4)			
M 1	2L1.5	1M2	Slight change(PF)
M 2	2L1.5	1M2	Slight change(PF)
M 3	2L1.5	1M2	Slight change(PF)
Positive Control	2L1.5	1M2	Slight change(PF)

Table 3. Changes observed in restoration material

Medium	Change observed
GIC Restoration (N2)	
M 1	No changes (NF)
M 2	Corroded (NF)
M3	Became brown colour (NF)
Positive Control	Material deposited on the restoration (NF)
Sealed portion and unsealed portion of crown (N3)	
M 1	Difference can be observed (PF)
M 2	Sealed material corroded off (NF)
M3	No changes (NF)
Positive Control	Difference can be observed (PF)

5.1 Positive Finding (PF)/ Negative Finding (NF)

- The natural tooth which was preserved in coconut oil had shown some improvement in the shade (lighter) and appeared glossy (PF).
- Olive oil did not give any improvement on the tooth. The colour of GIC restoration became brown (NF).
- The tooth preserved in lime juice resulted in corrosion of enamel and became chalky. The GIC restoration from the tooth corroded off and left a void (NF).

6. Discussion

The colour of the crown varies depends on the thickness, reflection, translucency and variations in the degrees of

calcification of enamel and also on the type of dentition. In permanent dentition, the thickness of enamel on the incisal/occlusal third of the tooth are thicker than the cervical third of the crown. This is the reason why, the cervical third of the crown appears darker than the middle and incisal third. The normal colour of the primary tooth enamel is bluish white whereas in permanent the colour varies from greyish white, greyish yellow to yellowish white. This is because of increased thickness of dentin and decreased thickness of enamel in permanent teeth.

The discoloration/stains of the tooth occur due to various etiological factors. The factors might be because of deposition of residue of food and beverages, medications and tobacco. Discoloration of the tooth can be classified as extrinsic and intrinsic stains. In dental practice, the

stains can be removed by prophylactic procedures along with use of tooth pastes and also by performing micro-abrasive and bleaching procedures. Other than dental procedures, one of the natural methods advocated for obtaining whiter teeth is oil pulling using coconut oil. The present study attempted to investigate the effects of various types of natural oils on the teeth and restorative material. The findings of our experiment are as follows.

6.1 Natural tooth

- In medium 1, the tooth showed a shade lighter and appears to have more gloss (Figure 1).
- In medium 2, the tooth turned to chalky white and enamel appeared corroded (Figure 2).
- In medium 4, the tooth appeared a shade lighter (Figure 4).

6.2 Acrylic Tooth

- All the teeth changed to a similar shade, a slight change observed to a lighter shade (Figure 1, 2, 3, 4).

6.3 GIC Restoration

- In medium 2, the GIC restoration has corroded leaving a void on the crown surface (Figure 2).
- In medium 3, the GIC restoration turned to a yellowish brown colour (Figure 3).
- In medium 4, the GIC restoration, material deposited on the surface (Figure 4).

6.4 Sealed Portion and Unsealed Portion of Tooth

- In medium 1, difference in tooth shade can be seen between sealed and unsealed portion (Figure 1).
- In medium 2, sealed material corrodes off (Figure 2).
- In medium 4, difference in tooth shade can be seen between sealed and unsealed portion (Figure 4).

7. Conclusion

To analyse the effects of oil pulling on hard tissue of the tooth require a highly controlled experimental setting as the effects depend on several factors such as type of oil utilized, exposure time of oil in the mouth and oral hygiene of the patients. The present study was done on extracted tooth preserved in oil for a period of seven days and does not accurately recreate or simulate oil pulling in the oral cavity. However, in our study, coconut oil, as such, had shown whitening effect on the tooth, also found to have had no effect on the restorative material and can be preferred over other types of oil such as olive oil which was found to have a darkening effect on restorative materials.

8. References

1. Naseem M, Khiyani MF, Nauman H, Zafar MS, Shah AH, Khalil HS. Oil pulling and importance of traditional medicine in oral health maintenance. *International Journal of Health Sciences*. 2017; 11(4):65–70.
2. Gbinigie O, Onakpoya I, Spencer E, McCall MacBain M, Heneghan C. Effect of oil pulling in promoting oral dental hygiene: A systematic review of randomized clinical trials. *Complementary Therapies in Medicine*. 2016; 26:47–54. <https://doi.org/10.1016/j.ctim.2016.02.011> PMID:27261981
3. Singh A, Purohit B. Tooth brushing, oil pulling and tissue regeneration: A review of holistic approaches to oral health. *Journal of Ayurveda and Integrative Medicine*. 2011; 2(2):64–8. <https://doi.org/10.4103/0975-9476.82525> PMID:21760690 PMCID:PMC3131773
4. Wheeler M, Friedl Z. Effect of oil pulling on tooth whitening in vitro. *Journal of Advanced Oral Research*. 2016; 7(1):20–3. <https://doi.org/10.1177/2229411220160104>
5. Nam S-H, Kwun H-S, Cheon S-H, Kim H-Y. Effects of whitening toothpaste on color change and mineral contents of dental hard tissues. *Biomedical Research*. 2017; 28(9):3832–6.