

Case Report

A case report of fordyce granules with leukoplakia: Ectopia with leukoplakia

Kavina Sundararajan¹, Twinkle Josy¹, Mathew Jacob²

¹Intern, ²Associate Professor, Department of Oral Pathology and Oral Microbiology, Vinayaka Mission's Sankarachariyar Dental College, Vinayaka Mission's Research Foundation (Deemed to be university), Salem, Tamil Nadu, India.



Corresponding author:

Mathew Jacob,
Associate Professor,
Department of Oral Pathology
and Oral Microbiology,
Vinayaka Mission's
Sankarachariyar Dental College,
Vinayaka Mission's Research
Foundation (Deemed to be
university), Salem, Tamil Nadu,
India.

docere_mathew@yahoo.co.in

Received : 29 July 2021

Accepted : 31 August 2021

Published : 08 December 2021

DOI

10.25259/JADE_11_2021

Quick Response Code:



ABSTRACT

Leukoplakia is a potentially malignant disorder that clinically presents as white lesion that cannot be scrapped off. It is associated with the habit of tobacco use, however, other factors have also to shown increase the risk of occurrence. Fordyce granules are not a disease per se but does appear as yellow spots in the oral cavity which can be easily identified clinically. The present article reports an interesting case of a patient with Leukoplakia and Fordyce granules underlying the white patch which was muffled in clinical examination and evident in histological diagnosis.

Keywords: Leukoplakia, Fordyce's granules, Ectopia, Potentially malignant disorder

INTRODUCTION

Leukoplakia is a potentially malignant disorder that is associated with the use of tobacco in all forms but predominately with the habit of smoking. Leukoplakia usually presents clinically as white patches which have varied clinical appearances which can be deceptive at times and a biopsy is mandatory as the treatment of these lesions are based on the presence or absence of dysplasia in the histopathology report.

This article presents an interesting case report of patient with Leukoplakia with no evidence of Fordyce granules clinically, however, seen histologically.

CASE REPORT

A 47-year-old male patient reported to the Department of Oral Medicine and Radiology with chief complaint of white discoloration on the right cheek that developed few weeks back. Patient's history revealed of habit of chewing tobacco for the past 4 years. Intraoral examination had shown a diffuse white patch approximately 6 × 5 cm in size on the buccal mucosa as shown in Figure 1. The lesion was non tender and not scrapable. Based on history and clinical findings a provisional diagnosis of leukoplakia was given. For confirmatory diagnosis, a punch biopsy was done and sent for histological diagnosis to the department of Oral Pathology and Oral Microbiology.

The histopathological features of the lesion had shown hyperplastic parakeratinized stratified squamous epithelium exhibiting pseudoepithelial hyperplasia in many areas. Dysplastic features were also observed such as broad and flat rete pegs with basal cell hyperplasia, acanthosis, cellular pleomorphism, and nuclear changes of hyperchromatic nuclei with increased nucleus cytoplasmic

This is an open-access article distributed under the terms of the Creative Commons Attribution-Non Commercial-Share Alike 4.0 License, which allows others to remix, tweak, and build upon the work non-commercially, as long as the author is credited and the new creations are licensed under the identical terms.

©2021 Published by Scientific Scholar on behalf of Journal of Academy of Dental Education

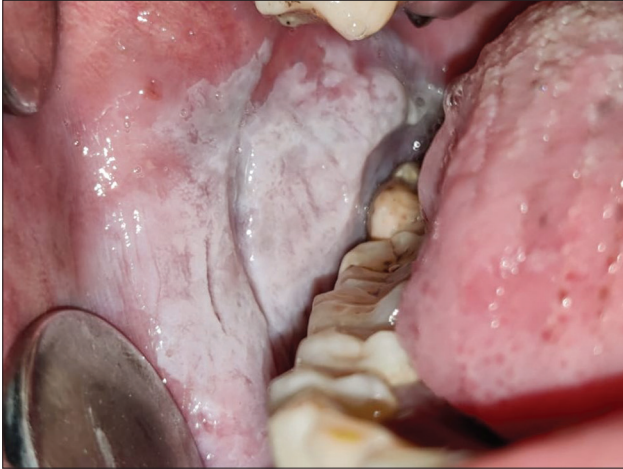

Figure 1: White patch on the right buccal mucosa along the occlusal plane.

ratio. These dysplastic features were evident in the lower two-thirds of the thickness of the epithelium. The underlying connective tissue was loose and fibrillar with blood vessels and inflammatory cells suggestive of moderate epithelial dysplasia that were compatible with clinical features of leukoplakia as shown in Figure 2. Another finding was the presence of multiple glandular structures in the connective tissue adjacent to the overlying epithelium. The morphology of cells and arrangement were consistent of sebaceous glands which is shown in Figure 3.

DISCUSSION

Leukoplakia is defined by WHO^[1,2] as “a white plaque of questionable risk having excluded (other) known diseases or disorders that carry no increased risk for cancer”. Chronic smoking, pipe smoking or tobacco chewing, irritation from the sharp teeth, ill-fitting dentures or crowns, UV radiations are some of the causes of leukoplakia. Sites of predilection are lateral and ventral tongue, floor of the mouth, alveolar ridge mucosa, and buccal mucosa, corner of the mouth, lip, and soft palate rarely. Clinically, the lesion is marked by unusual looking patches inside the mouth which is sensitive to touch, heat, spicy food, or other irritations. Fordyce granules^[3] which is not a disease but rather a developmental anomaly of the oral mucosa, is characterized by heterotopic collections of sebaceous glands at various sites in the oral cavity. Clinically, these granules appear as small yellow spots either discretely separated or forming relatively large plaques. These are most commonly found on the buccal mucosa and also in inner surfaces of the lips. Sebaceous glands are present in the oral mucosa in approximately 80% of the population. There is no specific treatment required for this condition unless esthetics is the main concern.

The present case is an interesting report of a patient who had a large diffuse white patch on the buccal mucosa but did not show the presence of Fordyce granules. It was interesting to

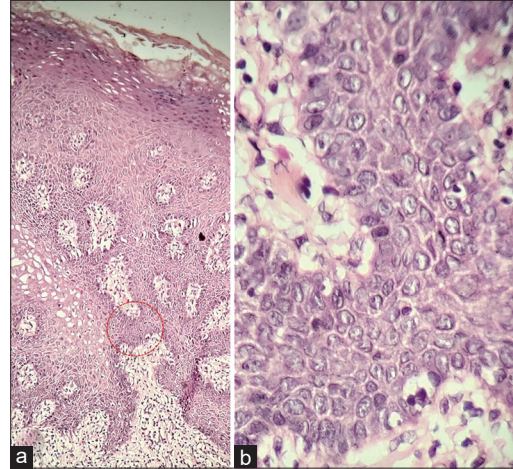


Figure 2: (a) Microscopic section of leukoplakia (H&E 10x), (b) inlet (H&E 40x).

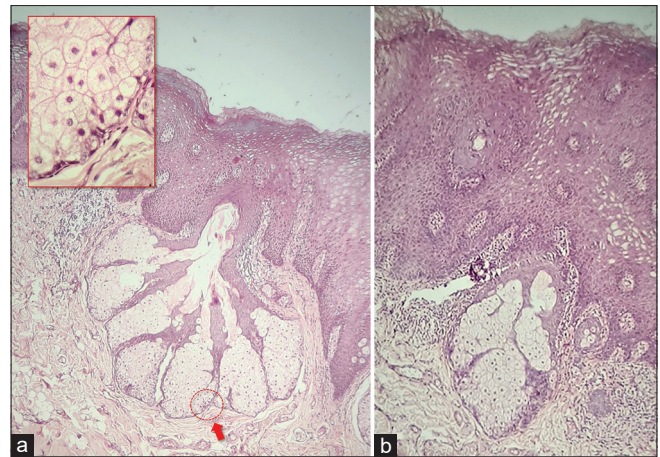


Figure 3: (a and b) Microscopic section of ectopic sebaceous glands (H&E 10x) inlet showing ectopic sebaceous follicle (H&E 40x).

note the presence of lobules of sebaceous cells beneath the epithelium with a central duct communicating the surface. These cells were polygonal with centrally located nucleus and abundant foamy cytoplasm. These features of Fordyce granules were appreciated only in the histopathological examination but not seen in the oral cavity. The absence of such typical yellow spots on the buccal mucosa could probably be due to thick whitish grey mucosa that could have masked the yellow spots and hence not making it clinically evident.

CONCLUSION

Fordyce granules are developmental anomaly of ectopic sebaceous glands that are seen at times in the oral cavity usually in the buccal mucosa. The present case was unique that at times, even with careful and thorough clinical examination, lesions such as leukoplakia, can mask an underlying anomaly which only ascertains the

importance of histological diagnosis in the specialty of oral pathology.

Declaration of patient consent

Patient's consent not required as patients identity is not disclosed or compromised.

Financial support and sponsorship

Nil.

Conflicts of interest

There are no conflicts of interest.

REFERENCES

1. Mortazavi H, Baharvand M, Mehdipour M. Oral potentially malignant disorders: An overview of more than 20 entities. *J Dent Res Dent Clin Dent Prospects* 2014;8:6-14.
2. Neha A, Sumit B. Leukoplakia potentially malignant disorder of oral cavity a review. *Biomed J Sci Technol Res* 2018;4:1126.
3. Lee JH, Lee JH, Kwon NH, Yu DS, Kim GM, Park CJ, *et al.* Clinicopathologic Manifestations of patients with Fordyce's spots. *Ann Dermatol* 2012;24:103-6.

How to cite this article: Sundararajan K, Josy T, Jacob M. A case report of fordyce granules with leukoplakia: Ectopia with leukoplakia. *J Acad Dent Educ* 2021;7:46-8.