

Original Article

Lingual split bone technique – Revisited as a standard operating procedure for surgical removal of third molar during COVID pandemic

Sushmitha Mohan¹, Annamalai Thangavelu², Aravindraj³

¹Intern, ²Professor, ³Postgraduate, Department of Oral and Maxillofacial Surgery, Rajah Muthiah Dental College, Annamalai University, Cuddalore, Tamil Nadu, India.

***Corresponding author:**

Sushmitha Mohan,
Department of Oral and
Maxillofacial Surgery, Rajah
Muthiah Dental College,
Annamalai University,
Cuddalore, Tamil Nadu, India.

shiningsushmitha@gmail.com

Received : 17 April 2021

Accepted : 31 May 2021

Published : 05 August 2021

DOI

10.25259/JADE_3_2021

Quick Response Code:



ABSTRACT

Objectives: The objective of the study is to revisit the forgotten art of Lingual split bone technique during the COVID pandemic as a Standard Operating Procedure (SOP) for the surgical removal of impacted mandibular third molars. It was originally introduced in early 90's by Sir William Kelsey Fry and also we have compared its advantages over the bone guttering technique.

Materials and Methods: Twenty seven cases were operated during COVID pandemic in our institution using Davi's modified lingual split technique under strict COVID protocol.

Results: All impacted mandibular third molars were successfully removed. With regards to post-operative complication; 3 patients had nerve injury (11%), 2 patients had lingual paraesthesia (7.6%), 1 patient had alveolar osteitis (3.8%), 2 patients had postoperative infection (7.6%), 3 patients had trismus (19%). The overall success rate was 100%. Also the results of a comparison between bone guttering and chisel-mallet technique were stated.

Conclusion: The use of lingual split bone technique deserves consideration during this COVID time as an alternate for bone guttering in surgical removal of third molar as it ensures minimal cross infectivity rate among both dentists and patients. Thus, patient care can be delivered with confidence even during pandemic.

Keywords: Impacted tooth, Third molar removal, Kelsey fry, Davis method, COVID SOP, Lingual split technique

INTRODUCTION

The lingual split bone technique is a quick and clean technique introduced by Sir William Kelsey Fry in 1933 and popularized by Terence G Ward in 1956.^[1] This technique takes advantage of the lingual plate by fracturing it; thus, preventing the buccal plate and external oblique ridge. It is highly indicated in those young patients with elastic bone and it has been the best alternate option for bone guttering during the COVID era. Sir Davis opted for a modification in 1983 to overcome the drawbacks encountered in Kelsey Fry's technique. However, the technique has not gained much acceptance apparently and fallen out of favor over the decades. However still, it was much revisited during COVID as a standard operating procedure (SOP) for surgical removal of mandibular third molar.

MATERIAL AND METHODS

The basic armamentarium required for the removal of impacted mandibular third molars is as follows; 2% lidocaine with adrenaline, mouth prop; BP blade (No:15); 0.9% saline solution;

This is an open-access article distributed under the terms of the Creative Commons Attribution-Non Commercial-Share Alike 4.0 License, which allows others to remix, tweak, and build upon the work non-commercially, as long as the author is credited and the new creations are licensed under the identical terms.

©2021 Published by Scientific Scholar on behalf of Journal of Academy of Dental Education

retractors; Gardner chisel 4 mm and Chandler chisel 5 mm; Mead mallet (17 cm); osteotome; sutures (3–0 silk); and curved needles.

The methods of interest here are

1. Kelsey Fry's lingual split bone technique^[2]
2. Davi's lingual split bone technique^[2]

At our institution; during COVID time, 27 cases were operated using Davi's modified lingual split technique under strict COVID protocol [Table 1]. Pre-operative OPG and IOPA were taken, and the level of difficulty in impaction removal was assessed. Routine blood investigations were carried out and the patient was directed toward surgical removal of impacted tooth. The patient was painted and draped with drape sheets under all aseptic conditions. Local anesthesia was achieved using standard inferior alveolar nerve block and long buccal nerve block. Both Ward's and Modified Ward's incisions were used depending on the type of impaction; then, full-thickness mucoperiosteal flap was raised.

A point of purchase was made in the buccal side, to place the elevator. Distolingual split was made by placing the chisel parallel to the external oblique ridge, few taps were given using mallet. Thus, a window was created on distolingual side. Tooth was luxated by elevating it on buccal side, it was thus delivered on lingual side; without fracture of lingual plate. Thus, lingual bone loss and lingual nerve damage were avoided in this Davi's method.

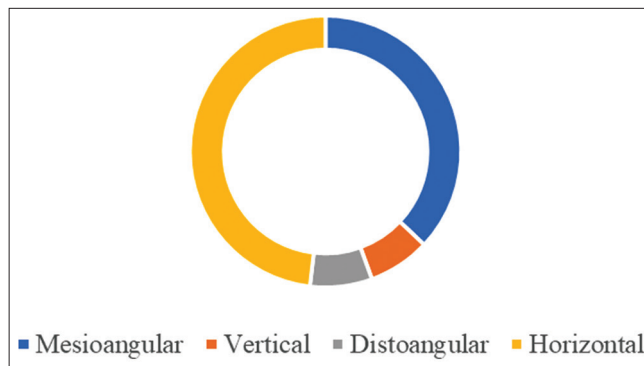
Of those 27 cases operated at our institution, 10 cases were of mesioangular type; 2 were of distoangular type; 13 were of horizontal type; and 2 were vertically impacted [Graph 1]. Among those 27 cases, almost 17 patients were male and the remaining were female. Furthermore, the images of a case, operated using Davi's method for removal of a mesioangular impaction, are added here [Figures 1-8].

RESULTS

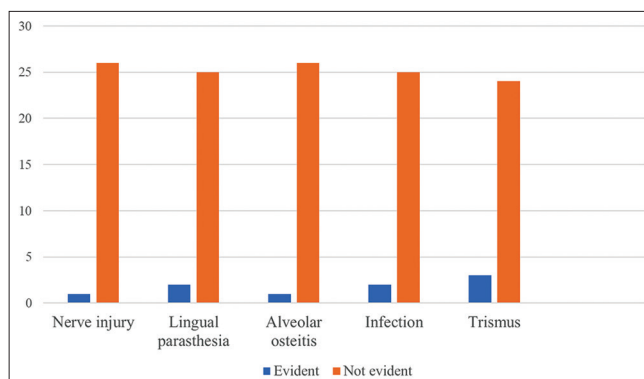
All impacted mandibular third molars were successfully removed; the success rate was 100%. The average time of operation was 13 min. No major intraoperative complication occurred during the procedure.

Furthermore, with regard to post-operative complication [Graph 2], 3 patients had nerve injury (11%), 2 patients had lingual paresthesia (7.6%), 1 patient had alveolar osteitis (3.8%), 2 patients had post-operative infection (7.6%), and 3 patients had trismus (19%).

Two cases with lingual nerve paresthesia were reassessed, they achieved full recovery within 2 months by neurotrophic drug treatment. Two cases developed post-operative infection and recovered by draining and antibiotic administration within 1 week. Using visual analog scale, intraoperative pain



Graph 1: Types of impaction.



Graph 2: Incidence of post-operative complications.

was recorded, in which three patients had severe pain, eight patients had moderate pain, and 16 patients had mild pain.

Two charts, one on impaction type and other on post-operative complication rate, are also added here.

DISCUSSION

Although multiple options are available for the removal of impacted tooth; lingual split bone technique is our topic of concern, this lingual split bone technique has not gained much appreciation because of the associated disadvantages such as lingual nerve damage and lingual soft-tissue hemorrhage. Although many oppositions were stated against this technique, Davi's technique was the talk of town at COVID time as it was stated as a SOP under COVID guidelines. The major advantages were minimal periosteal reflection; preservation of lingual periosteum and lingual nerve; minimal bone loss; and socket saucerization which result in reduced size of the residual clot.

Studies have shown that aerosols from highly virulent pathogens like severe respiratory syndrome-coronavirus (SARS-CoV) can travel more than 6 feet. In such instance, while performing dental procedures like bone guttering, water coolant could generate aerosols. When combined with body

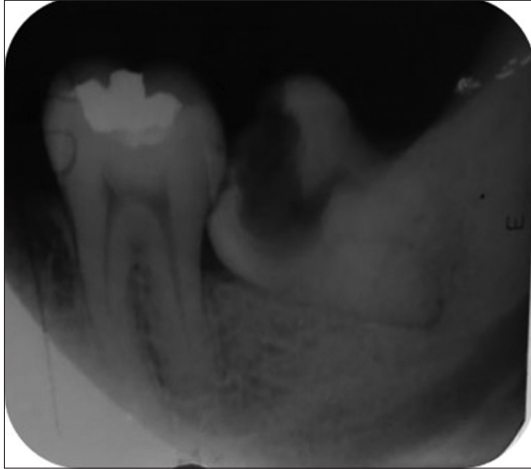

Figure 1: Pre-operative IOPA

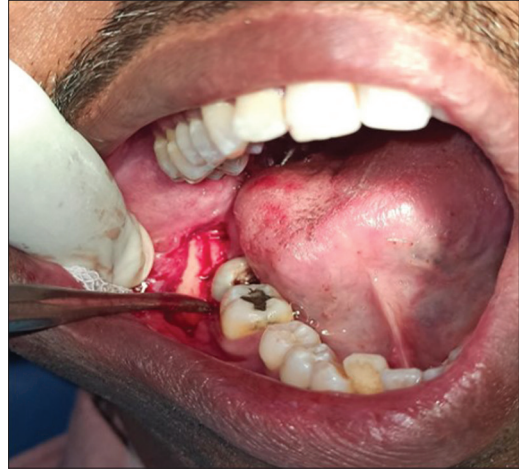

Figure 4: Vertical stop cut.

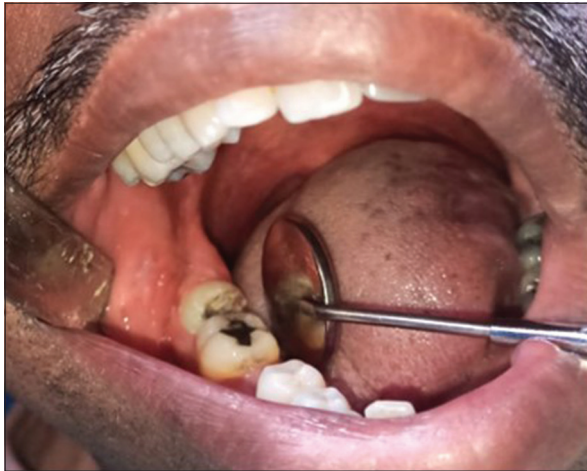

Figure 2: Pre-operative intraoral view.

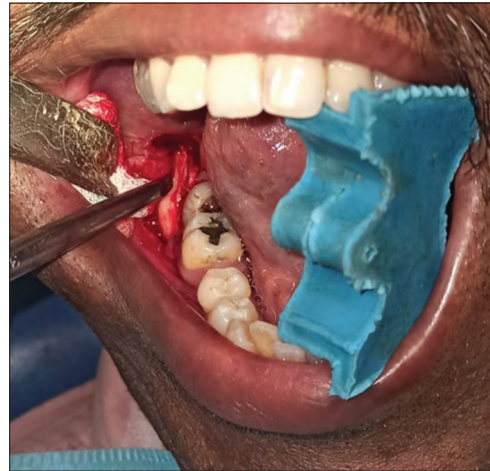


Figure 5: Horizontal stop cut.

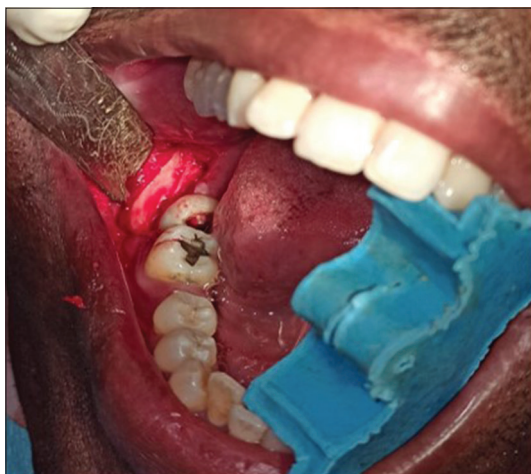

Figure 3: Mucoperiosteal flap raised.

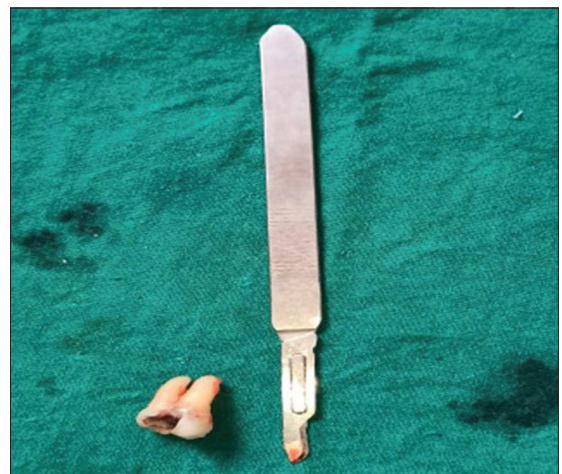


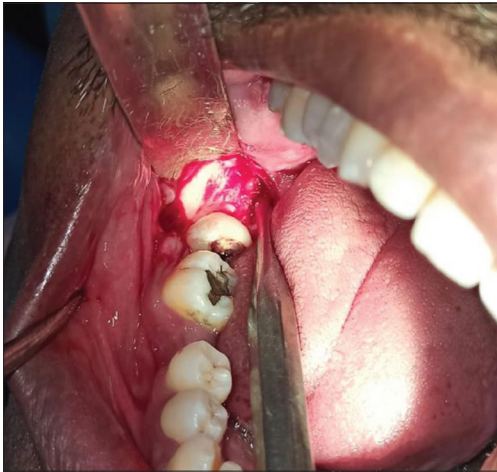
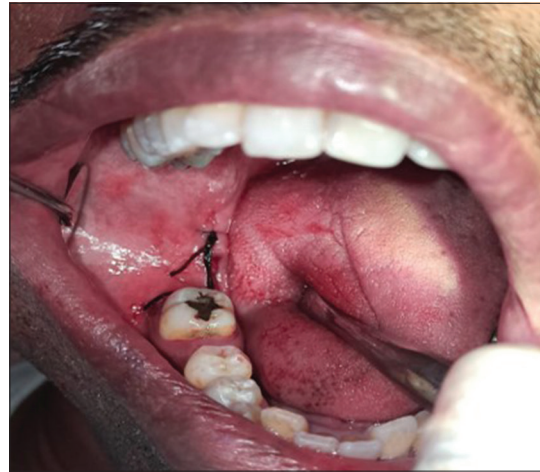Figure 6: Distolingual cut.

fluids like saliva, they become bioaerosols. These bioaerosols are source of infection in general but to be specific; aerosols

from the patients who are carriers of this SARS-CoV virus are highly life threatening for the dental professionals. Hence, we

Table 1: List of patients treated by Davi's technique.

S. No.	Name	Age	Sex	Impaction type	Time taken for removal (minutes)	Intraoperative bleeding	Post-operative complications
1.	Punitha	34	F	Mesioangular	17	Within normal limits	Evident
2.	Raja	26	M	Horizontal	16	Within normal limits	Evident
3.	Shankar	25	M	Horizontal	16	Within normal limits	Not evident
4.	Sruthi	18	F	Mesioangular	13	Within normal limits	Not evident
5.	Devi	39	F	Mesioangular	15	Within normal limits	Not evident
6.	Pradhap	33	M	Horizontal	14	Within normal limits	Not evident
7.	Kavin	21	M	Distoangular	19	Mild bleeding	Evident
8.	Sundhar	37	M	Horizontal	19	Within normal limits	Not evident
9.	Ramalingam	38	M	Horizontal	15	Within normal limits	Not evident
10.	Priya	41	F	Mesioangular	17	Within normal limits	Not evident
11.	Deepthi	22	F	Horizontal	15	Within normal limits	Not evident
12.	Ravi	40	M	Mesioangular	19	Mild bleeding	Evident
13.	Kishore	35	M	Mesioangular	17	Within normal limits	Not evident
14.	Sarath	35	M	Horizontal	20	Excessive bleeding	Evident
15.	Ashwin	25	M	Vertical	14	Within normal limits	Not evident
16.	Sowmiya	39	F	Mesioangular	19	Within normal limits	Not evident
17.	Basheer	19	M	Horizontal	16	Within normal limits	Not evident
18.	Surya	24	M	Vertical	20	Mild bleeding	Evident
19.	Sam	22	M	Horizontal	16	Within normal limits	Not evident
20.	Bhuvana	21	F	Distoangular	17	Within normal limits	Not evident
21.	Divya	32	F	Mesioangular	17	Within normal limits	Not evident
22.	Sofiya	37	F	Horizontal	15	Within normal limits	Not evident
23.	Vishwa	23	M	Horizontal	16	Within normal limits	Not evident
24.	Ramya	23	F	Mesioangular	17	Within normal limits	Not evident
25.	Karan	29	M	Horizontal	15	Within normal limits	Evident
26.	Tamilselvan	33	M	Horizontal	15	Within normal limits	Not evident
27.	Karthik	23	M	Mesioangular	19	Within normal limits	Not evident

**Figure 7:** Extracted tooth.**Figure 8:** Wound closure.

thought of revisiting this old technique of chisel and mallet as an alternative for bone gutting.

The reason behind opting this as an SOP is that; it makes use of hand instruments like chisel and mallet; wherein, the aerosol production is almost nil [Table 2].^[3] Also many exponents point out that the technique is safe, timesaving

and causes minimal tissue injury and minimal complications as long as it is used correctly.^[4]

The present topic of interest, Davi's method, was used at COVID time in the removal of 27 impacted 3rd molars and it even expressed a very low complication rate. Some earlier reports have mentioned about post-operative

Table 2: Comparison between guttering and chisel technique.

Chisel versus Bur ^(3,4)	Chisel	Bur
Technique	Difficult	Easy
Bone healing	Good	Minimal
Post-operative infection	Less	More
Post-operative edema	Less	More
Dry socket	Less	More
Aerosol production	Nil	Maximum

sequelae like the incidence of alveolar osteitis; labiomental paresthesia; lingual paresthesia; and infection in about 598 extractions of impacted lower molar by Davi's method.^[5]

Here is a list of reviews regarding the lingual split bone technique from various authors.

- W. Howard Davis stated that, in Davi's method, the principle involved is to provide a distolingual split and leaving the lingual plate attached to the periosteum. Only those portions of bone that is not attached to the periosteum are removed
- Chin-Jyh Yeh offered for a new idea while using lingual split technique in which he stated that, in this technique, impacted third molar is to be removed in one piece, and may be used as a donor tooth to replace an unrestorable molar
- David A Hochwald insisted that the complications encountered during lingual split bone technique were transient and resolved within 5 months
- Kanwar Inderjot Singh made a comparative study and stated that, Davis method is comparatively less time consuming, also clinically presents less swelling, and associated with less pain
- Ge, Jing, Yang, Chi made an advanced study on lingual split bone technique using piezo surgery and stated that it is an effective and minimally invasive procedure for lingual positioned bony impacted mandibular third molars extraction.

CONCLUSION

Here in this paper, we have emphasized the importance of lingual split bone technique during the COVID pandemic. Although it has been in practice since a century; it has been revisited highly during the pandemic. The reason behind adopting this technique is its least chance in transmitting the airborne infection. As the aerosol production is almost nil here, dentist can opt for surgical removal of third molar even during the pandemic. Any surgery can be approached in multiple ways; though one half of the door is shut, the other half is always ready to welcome us.

So be it COVID or any other pandemic; surgery always has a backup option; so we should always try to remember that every technique is unique in its own way, be it a conventional one or a recent trending one. Thus, this article aims in emphasizing the hope of carrying out dental emergencies with full confidence even during pandemic days.

Acknowledgment

Authors acknowledge sincere thanks for the constant motivation and guidance from Prof. Dr. Annamalai Thangavelu Sir.

Declaration of patient consent

The authors certify that they have obtained all appropriate patient consent.

Financial support and sponsorship

Nil.

Conflicts of interest

There are no conflicts of interest.

REFERENCES

1. Yeh CJ. Simplified split-bone technique for removal of impacted mandibular third molars. *Int J Oral Maxillofac Surg* 1995;24:348-50.
2. Rud J. Reevaluation of the lingual split-bone technique for removal of impacted mandibular third molars. *J Oral Maxillofac Surg* 1984;42:114-7.
3. Singh KI, Sharma A, Bali A, Malhotra A, Patidar DC, Tanwar K. Comparison of modified lingual split technique and conventional buccal bone cutting technique for the surgical extraction of impacted mandibular third molar. *Indian J Dent Sci* 2019;11:207-13.
4. Steel B. Lingual split versus surgical bur technique in the extraction of impacted mandibular third molars: A systematic review. *Oral Surg Oral Med Oral Pathol Oral Radiol* 2012;114:294-302.
5. Hochwald DA, Davis WH, Martinoff J. Modified distolingual splitting technique for removal of impacted mandibular third molars: Incidence of postoperative sequelae. *Oral Surg Oral Med Oral Pathol* 1983;56:9-11.

How to cite this article: Sushmitha M, Thangavelu A, Aravindraj. Lingual split bone technique – Revisited as a standard operating procedure for surgical removal of third molar during COVID pandemic. *J Acad Dent Educ* 2021;7(1):18-22.