

Case Report

# Concepts and consensus in surgical management of facial asymmetry – A case report

Sowmiya Srinivasan<sup>1</sup>, Annamalai Thangavelu<sup>2</sup>, K. Janarthanan<sup>3</sup>

<sup>1</sup>Intern, <sup>2</sup>Professor, <sup>3</sup>Associate Professor, Department of Oral and Maxillofacial Surgery, Rajah Muthiah Dental College and Hospital, Annamalai University, Chidambaram, Tamil Nadu, India.



**\*Corresponding author:**

Sowmiya Srinivasan,  
Intern, Department of Oral and  
Maxillofacial Surgery, Rajah  
Muthiah Dental College and  
Hospital, Annamalai University,  
Chidambaram, Tamil Nadu,  
India.

[sowmi4zumi@gmail.com](mailto:sowmi4zumi@gmail.com)

Received: 14 May 2023  
Accepted: 18 May 2023  
Epub Ahead of Print: 01 July 2023  
Published: 09 December 2023

DOI  
10.25259/JADE\_47\_2023

**Quick Response Code:**



## ABSTRACT

Growth and development of the head-and-neck are complex and early processes associated with higher chances of malformation. Any malformation of the hard or soft tissue of the head-and-neck leads to a common effect of facial asymmetry. Facial asymmetry is attributed to various other causes also. This article is about the significance of understanding the concepts in the management of facial asymmetry for a successful treatment outcome that satisfies the objectives and goals of the treatment and limits the complications.

**Keywords:** Hemifacial microsomia, Facial deformity, Free fat dermis, Facial asymmetry correction, Orthognathic surgery

## INTRODUCTION

Even before a woman is aware of the pregnancy, the embryological formation of head-and-neck takes place. Hence, there are higher risks of environmental and toxic damages to developing fetuses, resulting in congenital malformations. Sometimes, genetic-related factors can also cause malformations. Any abnormality of the hard and soft tissues of the face can lead to facial asymmetry.

The term “asymmetry” is used to refer to the differences that exist between two halves causing the imbalance between homologous elements.<sup>[1]</sup> However, a perfect bilaterally symmetrical face and body rarely exist. Every face shows a mild degree of asymmetry. According to some authors, asymmetry becomes obvious only when the skeletal deviation is at least 4 mm, below which it is usually not detectable.<sup>[2]</sup>

Comprehension of etiology, classification of particular facial asymmetry, and treatment modalities and indications are an absolute necessity for accurate quantitative and qualitative diagnosis for evolving a treatment plan and its successful outcome.

## CLASSIFICATION

Facial asymmetry can be caused by various reasons or deformities which could be congenital, developmental, or sometimes acquired. It may be attributed to either prenatal or postnatal cause. It could also have its origin from hard tissue, soft tissue, or combination of oral and maxillofacial structure. Facial asymmetry can be regarded as static or dynamic.<sup>[3]</sup>

Cheong and Lo have grouped the etiology of facial asymmetry into three categories<sup>[4]</sup> [Table 1].

## REVIEW OF LITERATURE

Cranio-mandibular asymmetries that occur during the growth period may be treated by a conservative approach with orthopedic and orthodontic management. It has demonstrated good results that has remained stable for a long period of time.<sup>[5]</sup>

Camouflage is one of the minimalistic approaches for mild asymmetry. Facial asymmetry due to muscle hypertrophy is managed conservatively to a certain extent with psychological counseling, medications such as muscle relaxants, anxiolytic drugs, and analgesics. Sometimes, dental restorations, and occlusal adjustments can help. A less invasive treatment modality for muscular hypertrophy caused asymmetry is botulinum toxin Type A. Botulinum toxin A is actually a powerful neurotoxin obtained from clostridium botulinum. It acts by inhibiting the neurotransmission mechanism in the muscle. This subsequently results in muscle atrophy. One of the drawbacks is the relapse after 6 months. In cases of acquired asymmetry, in conditions like fibrous dysplasia conservative management like curettage, contouring abnormal bones, and bone grafting are performed based on its severity.<sup>[6]</sup>

A thorough knowledge on what a particular treatment option can provide in terms of aesthetic aspect and functional aspect is important to choose between invasive and non-invasive management for skeletal imbalance cases. Surgical corrections are preferred for cases with high severity and complications and after the completion of bone growth. Sometimes, the management of asymmetry involves a combination of surgical as well as conservative treatment like surgery in one jaw and dental compensation in the other.<sup>[2]</sup> Sagittal split ramus osteotomy is routinely performed for mild-to-moderate asymmetry (7–8 mm). Intraoral vertical ramus osteotomy is done when asymmetry is

more than 8 mm. Maxillary correction is done by LeFort I osteotomy procedure. These procedures can be performed by either “single splint technique” or “two splint technique” based on the condition. During the surgical procedure, facebow plays a key role in orienting the maxillomandibular complex in relation to the midline.<sup>[7]</sup>

MEDPOR porous polyethylene implant, an alloplastic material has proved to achieve a varying degree of success in soft-tissue augmentation. Similarly, nanogel and tissue expanders are currently in practice for various soft-tissue procedures with their own pros and cons.<sup>[8]</sup> Soft-tissue corrections should be planned only after complete healing of the skeletal components and assessment of their function in the post-operative position.<sup>[9]</sup>

Facial asymmetry due to radiotherapy induced growth center inhibition in children can be managed by distraction osteogenesis. Fat transfer also gives promising results to manage asymmetry in irradiated children without any persistent complications as of study carried out by Faghahati *et al.*<sup>[10]</sup>

As discussed earlier certain asymmetries could be managed simply by anti-inflammatory drugs and lipofilling while some conditions require extensive orthognathic surgeries. Therefore, understanding the cause of asymmetry and different management protocols are essential for building an ideal treatment plan. Silicone injections and acrylic prostheses are other good options, while other practicable treatment alternatives include autogenous fat grafts, cartilage grafts, and bovine collagen.<sup>[3]</sup> In recent days, mild and moderate cases are managed with liposuction and lipofilling to restore the esthetics in asymmetric face. A fusion of surgical and non-surgical management is sometimes required for a successful outcome in treating severe cases of Pierre-robin syndrome.<sup>[11]</sup>

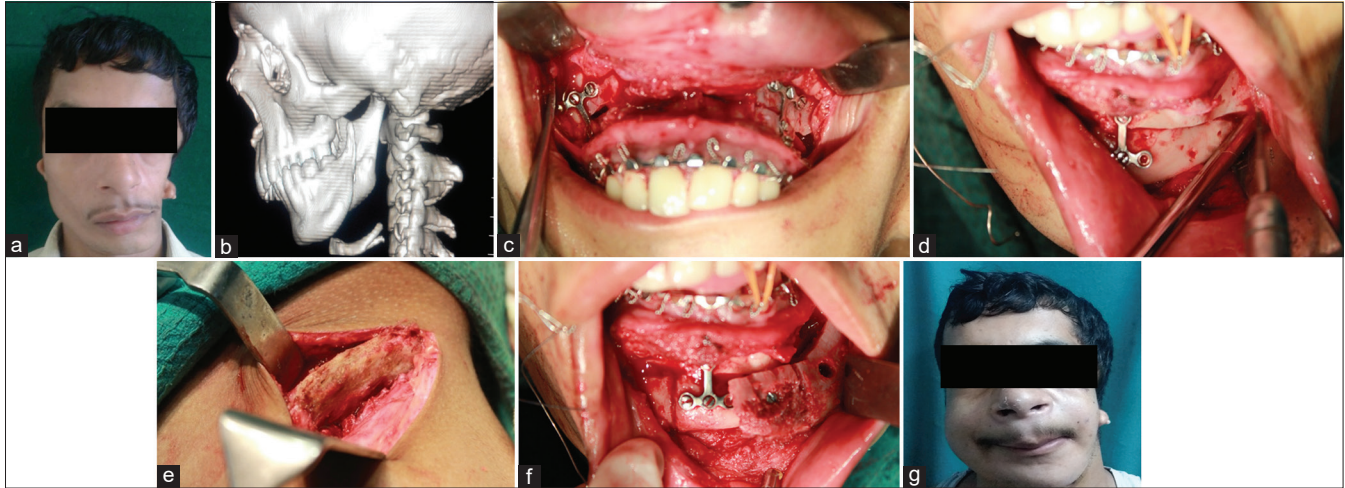
## CASE REPORT 1

A 30-year-old male patient reported a complaint of facial asymmetry since birth [Figure 1a]. Extraoral examination revealed an asymmetric face with depressed appearance on the left side, bilateral rudimentary right pinna, and the presence of a preauricular skin tag. Left maxilla and zygoma of the patient were smaller than those on the right side. The left eye was placed relatively at a lower level than that on the right. There was restriction of left lateral protrusive movements of the mandible. On palpation, the left middle third of the face felt depressed, temporomandibular joint movements were absent, and external auditory meatus were absent.

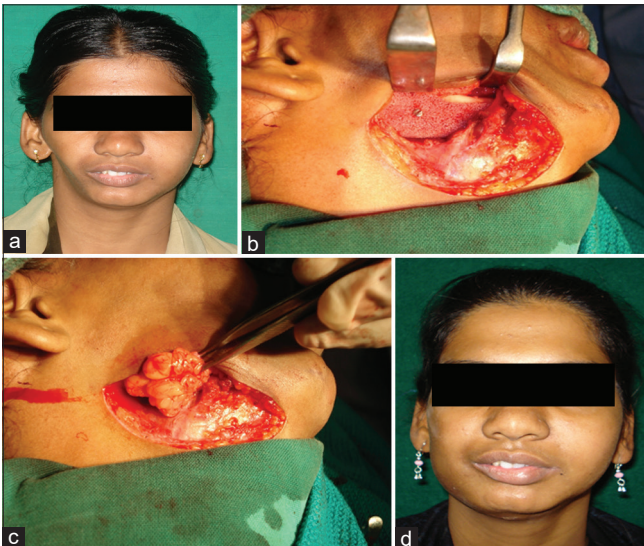
On intraoral examination, there was posterior crossbite and a canted occlusal plane. Anterior border of the left ramus was non-palpable. Orthopantomogram and computed tomography [Figure 1b] revealed a complete absence of left ramus, condyle,

**Table 1:** Cheong and Lo have grouped the causes of facial asymmetry into three categories.

| Congenital                 | Developmental | Acquired                          |
|----------------------------|---------------|-----------------------------------|
| Cleft lip and palate       | Cause unknown | Temporomandibular joint ankylosis |
| Tessier craniofacial cleft |               | Facial trauma                     |
| Hemifacial microsomia      |               | Childhood radiotherapy            |
| Neurofibromatosis          |               | Fibrous dysplasia                 |
| Torticollis                |               | Other facial tumors               |
| Craniosynostosis           |               | Unilateral condylar hyperplasia   |
| Vascular disorders         |               | Romberg's disease                 |
| Others                     |               | Others                            |



**Figure 1:** (a) Gross facial asymmetry with arrested growth of the left side of face and preauricular skin tags, (b) computed tomography showing arrested growth of left mandible, (c) Le Forte I osteotomy and correction of canted occlusal plane, (d) sliding genioplasty, (e) harvesting bone graft from iliac crest, (f) augmentation of hypoplastic left mandible with graft, and (g) post-operative image.



**Figure 2:** (a) Gross facial asymmetry with hypoplastic right lower third of face, (b) MEDPOR placed in position after reshaping, (c) free fat dermis grafting for soft-tissue correction, and (d) post-operative image.

and the coronoid process. Correlation of clinical and radiological findings has led to the diagnosis of hemifacial microsomia. Surgical management by LeFort I osteotomy for the maxilla was performed in the standard fashion and the canted occlusal plane was corrected by superior impaction on the right side and fixed [Figure 1c]. Sliding genioplasty [Figure 1d] was performed to correct the deviated mandible, to balance the aesthetic E-line and midline. Bone graft was obtained from the iliac crest [Figure 1e] to augment the left maxilla and mandible and fixed with titanium plates [Figure 1f]. The postoperative image [Figure 1g] shows the augmentation achieved on the left side of the face.

## CASE REPORT 2

A 19-year-old female patient reported a complaint of facial asymmetry. Clinical examination [Figure 2a] revealed an asymmetric face with hypoplastic structures on the right side of the face. Investigations showed reduced width of the right body of mandible with soft-tissue deficiency. The treatment plan was made to surgically reconstruct the hypoplastic hard and soft tissue components. MEDPOR, a high-density porous polyethylene implant, was reshaped and fixed with titanium screws on the right body of the mandible [Figure 2b]. Free fat dermis was used for soft-tissue correction [Figure 2c]. The postoperative image [Figure 2d] shows the improved fullness on the right half of the face.

## DISCUSSION

Facial asymmetry is attributed to various causes of which developmental disorders form a major part. Understanding the disorder with its cause, manifestations are essential to plan a comprehensive, interdisciplinary treatment plan, and at the right growth period for the successful outcome. The second most common congenital craniofacial defect is hemifacial microsomia, after cleft lip and palate. It is characterized by the absence or underdevelopment of structures derived from first and second pharyngeal arches. Hemifacial microsomia represents a broad spectrum of manifestations which could be mild asymmetry and also to the extreme of complete absence of structures. This article discusses two extremes of manifestations of hemifacial microsomia and its management. There is a wide variation in treatment approaches and treatment options for every

**Table 2:** Management protocol based on new classification.

| Type I                | Type IIa  | Type IIb                                       | Type III  | Type IV  |
|-----------------------|---|--|---|--|
| Orthopedic management | Distraction osteogenesis+ orthopedic management | Distraction osteogenesis+orthopedic management | New Iliac or costochondral bone grafts+distraction osteogenesis (later) | Fibular-free flap+distraction osteogenesis (later if needed) |

patient presenting with hemifacial microsomia and the application of approach depends on the type, severity, and involvement of various structures. Thus, the treatment plan has to be customized for each patient. Orthognathic surgeries are effective when done after facial growth has occurred, while infants might need immediate or timely management for airway obstruction with tracheostomy for mandibular distraction. Orthognathic surgeries can be planned with Kaban's classification as guidelines [Table 2].

Soft-tissue augmentation can be employed to correct the soft-tissue deficiency persisting after 6 months of orthognathic surgery. Aspiration of fat from the lower abdomen is done with 16-gauge coleman cannula. To balance the facial symmetry, the micro autologous fat transplantation technique can be applied.<sup>[12]</sup>

## CONCLUSION

Correction of facial asymmetry presents a highly challenging scenario. The management protocol should be planned such that it fulfills the objectives for management which include efficient function, appealing esthetics, and cost-effectiveness. Among various treatment modalities available, the surgeon must be able to choose the optimal management and customize it according to the patient's need after a complete evaluation, analysis, and discussion with other disciplinary specialties for the complete well-being of the patient.

## Ethical approval

The research/study complied with the Helsinki Declaration of 1964.

## Declaration of patient consent

The authors certify that they have obtained all appropriate patient consent.

## Financial support and sponsorship

Nil.

## Conflicts of interest

There are no conflicts of interest.

## Use of artificial intelligence (AI)-assisted technology for manuscript preparation

The authors confirm that there was no use of artificial intelligence (AI)-assisted technology for assisting in the writing or editing of the manuscript and no images were manipulated using AI.

## REFERENCES

- Thiesen G, Gribel BF, Freitas MP. Facial asymmetry: A current review. *Dent Press J Orthod* 2015;20:110-25.
- Allgayer S, Mezzomo FS, Polido WD, Rosenbach G, Tavares CA. Orthodontic-surgical treatment of skeletal facial asymmetry: Case report. *Dent Press J Orthod* 2011;16:100-10.
- Iyer J, Hariharan A, Cao UM, Tran SD. Acquired facial, maxillofacial, and oral asymmetries-a review highlighting diagnosis and management. *Symmetry* 2021;13:1661.
- Cheong YW, Lo LJ. Facial asymmetry: Etiology, evaluation, and management. *Chang Gung Med J* 2011;34:341-51.
- Schmid W, Deregibus A, Mongini F. Conservative treatment of craniomandibular asymmetries during growth. A long term study. *Prog Orthod* 2007;8:62-73.
- Lee JS, fitzgibbon EJ, Chen YR, Kim HJ, Lustig LR, Akintoye SO, *et al.* Clinical guidelines for the management of craniofacial fibrous dysplasia. *Orphanet J Rare Dis* 2012;7 Suppl 1:S2.
- Chen YR, Lo LJ, Kyutoku S, Noordhoff MS. Facial midline and symmetry: Modified face bow. *Plast Reconstr Surg* 1992;90:126-8.
- Andrade NN, Mathai P, Aggarwal N. Facial asymmetry. In: Bonanthaya K, Panneerselvam E, Manuel S, Kumar VV, Rai A, editors *Oral and Maxillofacial Surgery for the Clinician*. Singapore: Springer; 2021.
- Muller-Schelken H. Esthetic corrections in cases of orthognathic surgery. *Int J Adult Orthodon Orthognath Surg* 1989;4:229-37.
- Faghahati S, Delaporte T, Toussoun, G, Gleizal A, Morel F, Delay E. Treatment by fat tissue transfer for radiation injury in childhood facial cancer. *Ann Chir Plast Esthet* 2010;55:169-78.
- Van der Cruyssen F, Meeus J, Schoenaers J, Politis C. Parry Romberg syndrome: A long-term retrospective cohort study of 10 patients. *Oral Maxillofac Surg Cases* 2018;4:73-83.
- Yamaguchi K, Lonic D, Ko EW, Lo LJ. An integrated surgical protocol for adult patients with hemifacial microsomia: Methods and outcome. *PLoS One* 2017;12:e0177223.

**How to cite this article:** Srinivasan S, Thangavelu A, Janarthanan K. Concepts and consensus in surgical management of facial asymmetry – A case report. *J Academy Dent Educ*. 2023;9:86-9. doi: 10.25259/JADE\_47\_2023